

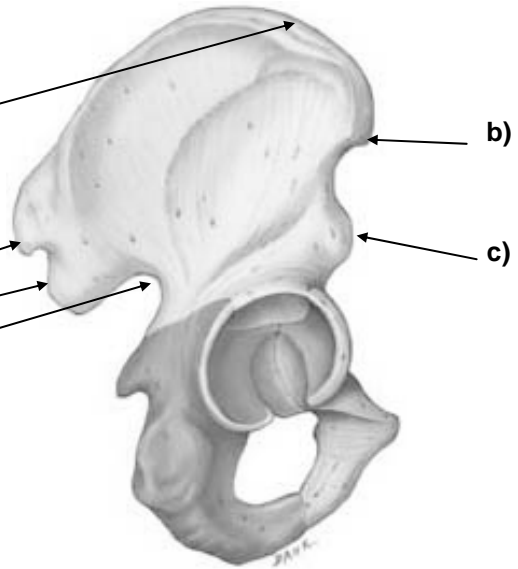
## PELVIC GIRDLE

Coxal (hip bones) consists of ilium, pubis, ischium.

1. Ilium: most superior part of hip bone

MARKINGS:

- a) **Iliac crest**: superior border of ilium
- b) **ASIS**: anterior superior iliac spine
- c) **AIIS**: anterior inferior iliac spine
- d) **PSIS**: posterior superior iliac spine
- e) **PIIS**: posterior inferior iliac spine
- f) **Greater sciatic notch**: lies below PIIS



2. Pubis: found in anterior and inferior parts

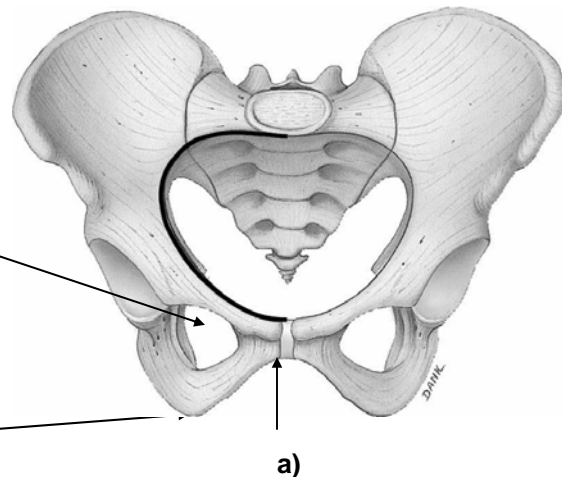
MARKINGS:

- a) **pubic symphysis**: anterior joint along mid-sagittal plane
- b) **obturator foramen**: large opening between ischium and pubis region

3. Ischium: found inferior and posterior aspect of coxal bone

MARKINGS:

- a) **ischial tuberosity**: most inferior part of ischium on which you sit aka your "sit bones"



Pelvis: basin-like structure formed by coxal, sacrum, and coccyx bones.

MARKINGS:

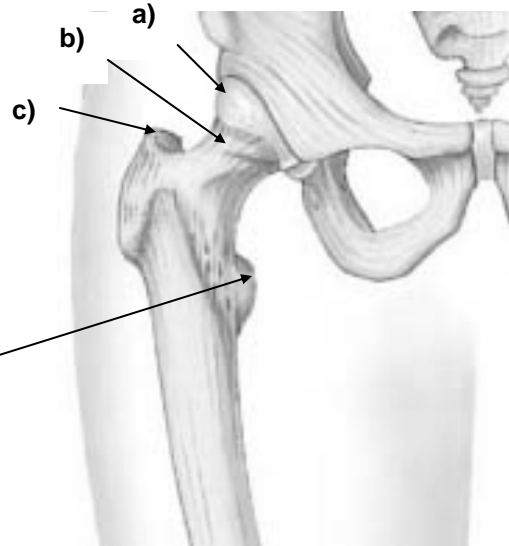
- a) **pelvic inlet**: superior opening
- b) **pelvic outlet**: inferior opening

## FEMUR

### 1. Proximal markings:

#### MARKINGS:

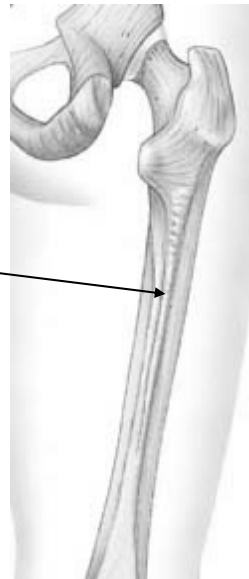
- a) **head**: rounded projection which articulates with acetabulum
- b) **neck**: constricted portion which lies below head
- c) **greater trochanter**: large lateral projection
- d) **lesster trochanter**: lies inferomedial to greater trochanter.



### 2. Shaft markings:

#### MARKINGS:

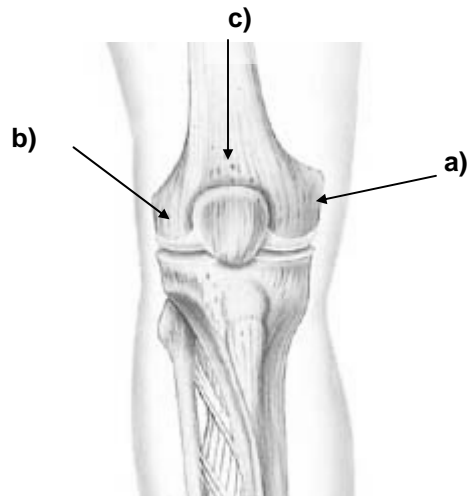
- a) **linea aspera**: posterior rough vertical ridge down length of bone



### 3. Distal markings:

#### MARKINGS:

- a) **medial condyles**: articulates with medial tibial condyle
- b) **lateral condyles**: articulates with lateral tibial condyle
- c) **patellar surface**: area between condyles on anterior surface

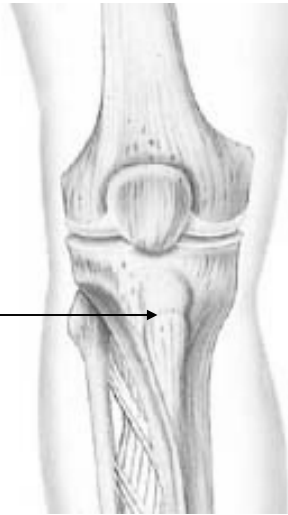


# TIBIA

1. Proximal markings:

MARKINGS:

**a) tibial tuberosity:** anterior projection;  
patellar ligament attachment site



2. Shaft markings:

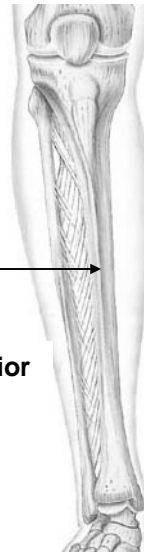
MARKINGS:

**a) interosseous border:** sharp ridge  
on posterior lateral aspect

**b) anterior crest:** anterior ridge  
which runs length (shin)

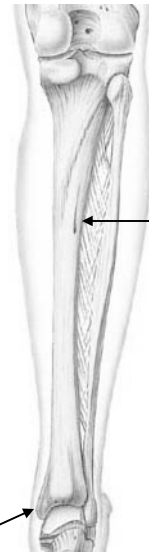


anterior



a)

posterior



3. Distal markings:

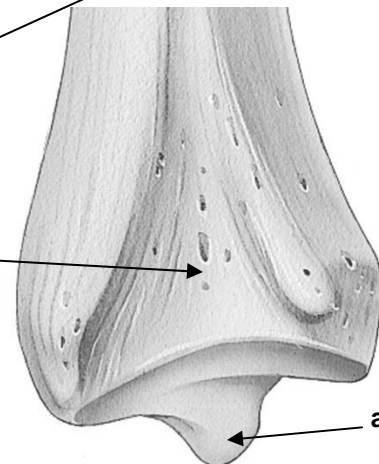
MARKINGS:

**a) medial malleolus:** articulates with  
talus; medial ankle bump

**b) fibular notch:** articulates with  
distal fibula



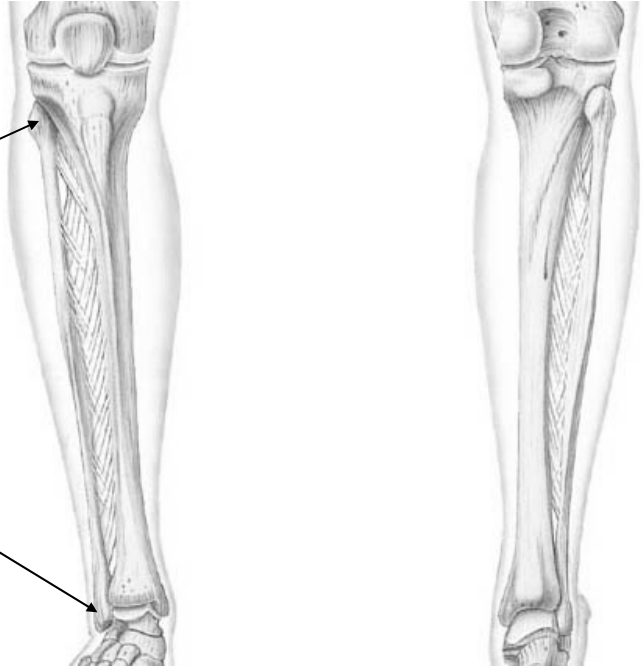
a)



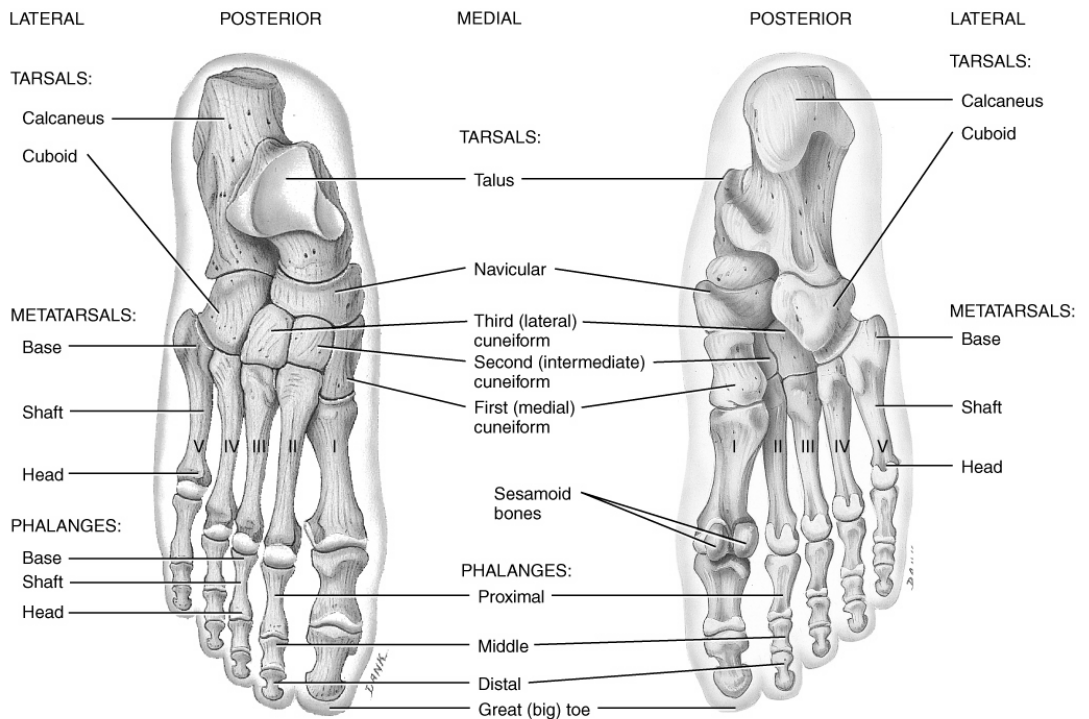
# FIBULA

MARKINGS:

- a) **head**: proximal fibula
- b) **lateral malleolus**: articulates with distal tibia at fibular notch; lateral ankle bump



# FOOT



(a) Superior view

(b) Inferior view

