

# ORTHOPEDICS

Dr. C. Hutchison  
Kurt Droll and Christopher Gallimore, editors  
Markku Nousiainen, associate editor

AN APPROACH TO ORTHOPEDICS . . . . .	2	FEMUR . . . . .	28
History		Femoral Diaphysis Fractures	
Physical Examination		Supracondylar Femoral Fracture	
Investigations		KNEE . . . . .	28
FRACTURES - GENERAL PRINCIPLES . . . . .	3	Common Knee Symptoms	
Radiographic Description of Fractures		Evaluation of Knee Complaints	
Clinical Features of Fractures		Ligamentous Injuries of the Knee	
Initial Management		Anterior Cruciate Ligament Tear	
Definitive Management		Posterior Cruciate Ligament Tear	
Open Fractures		Medial Collateral Ligament Tear	
Fracture Healing		Lateral Collateral Ligament Tear	
Complications of Fractures		Meniscal Tear	
Compartment Syndrome		Patella/Quadriceps Tendon Rupture	
Avascular Necrosis		Dislocated Knee	
SHOULDER . . . . .	8	PATELLA . . . . .	32
General Principles		Patella Dislocation	
Physical Examination of the Shoulder		Chondromalacia Patellae	
Acromioclavicular Joint Sprain		Patellar Fracture	
Clavicular Fracture		TIBIA . . . . .	33
Anterior Shoulder Dislocation		Tibial Plateau Fracture	
Posterior Shoulder Dislocation		Tibial Diaphysis Fracture	
Rotator Cuff Lesions		ANKLE . . . . .	34
Impingement Syndrome		Evaluation of Ankle Complaints	
Frozen Shoulder		Ankle Fractures	
HUMERUS . . . . .	12	Ligamentous Injuries	
Humeral Shaft Fracture		Recurrent Ankle Subluxation	
Proximal Humeral Fracture		FOOT . . . . .	36
ELBOW . . . . .	13	Talar Fracture	
Supracondylar Fracture		Calcaneal Fracture	
Radial Head Fracture		Achilles Tendonitis	
Olecranon Fracture		Achilles Tendon Rupture	
Elbow Dislocation		Plantar Fasciitis	
FOREARM FRACTURES . . . . .	14	Bunions	
General Principles		Metatarsal Fracture	
Nightstick Fracture		ORTHOPEDIC INFECTIONS . . . . .	39
Galeazzi Fracture		Osteomyelitis	
Complications of Forearm Fractures		Joint Infections	
WRIST . . . . .	15	PEDIATRIC ORTHOPEDICS . . . . .	41
Scaphoid Fracture		Fractures in Children	
Colles' Fracture		Evaluation of the Limping Child	
Smith's Fracture		Epiphyseal Injury	
Barton's Fracture		Pulled Elbow	
SPINE . . . . .	19	Developmental Dysplasia of the Hip	
Differential Diagnosis of Back Pain		Legg-Calve-Perthes Disease	
Degenerative Back Pain		Slipped Capital Femoral Epiphysis	
Cauda Equina Syndrome		Congenital Talipes Equinovarus (CTEV)	
Trauma		Scoliosis	
Thoracic and Lumbar Spine		BONE TUMOURS . . . . .	46
HIP . . . . .	23	Benign Bone Tumours	
Differential Diagnosis of Hip Pain		Benign Aggressive Bone Tumours	
Pelvic Fractures		Malignant Bone Tumours	
Hip Dislocation			
Hip Fracture			
Arthritis of the Hip			
AVN of the Femoral Head			

## HISTORY

## Identification

- identifying data
  - name, age, occupation, hobbies, hand dominance
- chief complaint
- past orthopedic history
  - injuries, past non-surgical treatment, past surgery
- other medical history
  - past surgery, allergies, medications, medical illnesses

## History of Present Illness

- important to obtain details regarding onset and progression of symptoms
- pain, weakness, deformity, stiffness, crepitus
  - OPQRST (Onset, Provoking / Alleviating factors, Quality, Radiation, Site, Timing)
  - muscular, bony, or joint pain ?
  - number of joints involved and symmetry of involvement
- inflammatory symptoms
  - morning stiffness (> 30 min), tenderness, swelling, redness, warmth
- mechanical/degenerative symptoms
  - worse at end of day, better with rest / worse with use
  - locking, giving way, instability
- neoplastic and infectious symptoms
  - pain which is constant, occurs at night
  - fever, night sweats
  - anorexia, fatigue, weakness, weight loss
  - P.T. Barnum Loves Kids: history of Prostate, Thyroid, Breast, Lung or Kidney cancer (most common mets to bone)
- activities of daily living
  - getting up, sitting down, using bathroom, combing hair, transferring
- referred symptoms
  - shoulder pain from the heart or diaphragm
  - arm pain from the neck
  - cardiac, pulmonary, GI history as needed
  - leg pain from back
  - back pain from the kidney, aortic aneurysm, duodenal ulcer

## PHYSICAL EXAMINATION

## Look, Feel, Move

- always examine the joint above and below
- look - skin, shape, position
  - SEADS: Swelling, Erythema, Atrophy, Deformity, Skin changes
- feel - palpate soft tissue, bony, or articular abnormalities
  - tenderness, palpable deformity, effusion, temperature
- move the affected joint(s)
  - active and passive ROM, crepitus, abnormal mobility
  - passive ROM > active ROM suggests soft tissue inflammation or muscle weakness
- neurovascular tests
  - pulse, reflexes, power, sensation
- power: use MRC scale
  - 0=no movement
  - 1=twitch
  - 2=movement with gravity eliminated
  - 3=movement vs gravity
  - 4=movement vs some resistance
  - 5=movement vs full resistance
- special tests depend on joint
  - e.g. Lachman, McMurray for the knee
- observe gait
  - walking, heel-to-toe, on heels, on toes
  - Trendelenburg gait in hip disorders
  - antalgic, high stepping, circumduction

## INVESTIGATIONS

## Diagnostic Imaging

- plain or contrast radiographs (sinography)
- CT/myelography, MRI, EMG / NCS
- <sup>99</sup>Tc (Technetium) bone scan
  - reflects osteoblastic activity or inflammatory reaction
  - positive with fractures, tumours
- gallium scan
  - positive when uptake on gallium is greater than on <sup>99</sup>Tc
  - reflects hypervascularity, taken up by leukocytes
  - positive with infection

## Blood Tests for Painful, Swollen Joint

- CBC, Rheumatoid Factor, ANA, ESR, C-reactive protein
  - use tests as warranted by history and physical

## Other Tests

- synovial fluid analysis
  - 3 C's: Crystals, Cytology, Cultures

## FRACTURES - GENERAL PRINCIPLES

- mechanism: remember the process leading to the fracture
  - traumatic
  - pathologic - tumour, metabolic bone disease, infection, osteopenia
  - stress - repetitive mechanical loading

## CLINICAL FEATURES OF FRACTURES

- pain and tenderness
- loss of function
- deformity
- abnormal mobility and crepitus (should not be elicited)
- altered neurovascular status

## INITIAL MANAGEMENT

- ABCDE's
- limb - attend to neurovascular status (above and below)
- r/o other fractures/injuries (especially joint above and below)
- r/o open fracture
- take an AMPLE history - Allergies, Medications, Past history, Last meal, Events surrounding injury
- splint fracture - makes patient more comfortable, decreases progression of soft tissue injury, decreases blood loss
  - don't forget analgesia
- x-ray fracture (rule of 2's) pre- and post-reduction

## RADIOGRAPHIC DESCRIPTION OF FRACTURES

- rule of 2's
  - 2 sides: bilateral
  - 2 views: AP and lateral
  - 2 joints: above and below
  - 2 times: before and after reduction
- patient identification
- identify views
- open or closed
  - gas in the soft tissue indicates an open fracture or soft tissue infection such as necrotizing fasciitis
- site
  - which bone
  - describe by thirds: proximal/middle/distal
  - extra-articular: diaphysis/ metaphysis
  - intra-articular

- ❑ type
  - spiral - rotational force, low energy
  - oblique - angular and rotational force
  - transverse - direct force, high energy
  - comminuted (> 2 pieces) - direct force, high energy
  - note: in distinguishing oblique from spiral fractures, if fracture line greater than 2x bone width --> spiral fracture
- ❑ soft tissue
  - calcification, gas, foreign bodies
- ❑ displacement (position of distal fragment with respect to proximal)
  - apposition/translation - describes what percentage of surfaces remain in contact
  - angulation - describes which way the apex is facing
  - rotation - distal fragment compared to proximal fragment
  - shortened - due to overlap or impaction

## DEFINITIVE MANAGEMENT

- ❑ goals
  - reduce
  - stabilize
  - rehabilitate

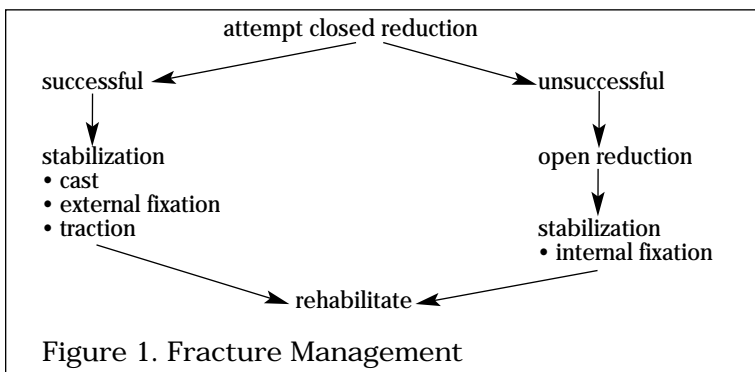


Figure 1. Fracture Management

### Reduction

- ❑ is reduction necessary?
  - may not be for clavicle, fibula, vertebral compression fractures
- ❑ reduce when amount of displacement unacceptable
- ❑ imperfect apposition may be acceptable while imperfect alignment is rarely acceptable
- ❑ closed when possible
- ❑ indications for open reduction - remember NO CAST
  - N - Non-union
  - O - Open fracture
  - C - neurovascular Compromise
  - A - intra-Articular fractures (require anatomic reduction)
  - S - Salter-Harris III, IV, V and/or special situations depending on site
  - T - polyTrauma

### Stabilization

- ❑ stabilize the fracture site but do not completely immobilize the limb if possible
- ❑ external stabilization
  1. splints/tape
  2. casts
  3. traction
  4. external fixator
- ❑ internal fixation
  1. percutaneous pinning
  2. extramedullary fixation (screws, plates, wires)
  3. intramedullary fixation (rods) - biomechanically advantageous

### Rehabilitation

- ❑ to avoid joint stiffness
- ❑ isometric exercises to avoid muscle atrophy
- ❑ ROM for adjacent joints
- ❑ CPM following rigid fixation of fracture allows joint motion to prevent stiffness for intra-articular fractures

- aftercast/splint removed and fracture healed --> resistive muscle strengthening
- evaluate bone healing (clinical, x-ray)

## OPEN FRACTURES

- emergency! fracture communicates with skin surface
- examine fracture carefully to classify

Table 1. Classification of Open Fractures

Size	Soft Tissue Injury	Antibiotics
Type 1 < 1 cm	minimal	Ancef
Type 2 >1cm	moderate; no dead soft tissue	Ancef
Type 3 >1cm	extensive muscle damage; includes gunshot wounds, major vascular injury barnyard injury	Ancef, Gentamycin, Flagyl

- initial management
  1. do not reduce open fractures unless there is neurovascular compromise from position of fracture
  2. remove gross debris i.e. turf, rocks
  3. all open fractures are contaminated, therefore obtain culture and cover wound with sterile dressing
  4. administer tetanus vaccine/booster (see indications below)
  5. start antibiotics
  6. splint
  7. NPO and prepare for OR
  8. irrigation and debridement,
  9. reduction and stabilization after I&D
- must get to OR within 6 hours, since risk of infection increases after this time
- re-examine, with possible repeat I&D in 48 hours

Table 2. Indications for Tetanus Vaccination

Tetanus History	Clean Wound		Dirty Wound	
	Td	TIG	Td	TIG
unknown or <3 Td doses	Y	N	Y	Y
>3 Td doses	N*	N	N**	N

\* Y if >10 years since last dose  
 \*\* Y if >5 years since last dose  
 Td=0.5 mL adsorbed tetanus toxoid  
 TIG=250 units tetanus immune globulin

### Complications of Open Fractures

- osteomyelitis
- soft tissue damage
- neurovascular injury
- blood loss
- nonunion

**FRACTURE HEALING**

Normal Healing

weeks 0-3	hematoma, macrophages surround fracture site
weeks 3-6	osteoclasts remove sharp edges, callus forms within hematoma
weeks 6-12	bone forms within the callus, bridging fragments
months 6-12	cortical gap is bridged by bone
years 1-2	normal architecture is achieved through remodelling

Figure 2. Stages of Bone Healing

Evaluation of Healing - Tests of Union

- clinical - no longer tender to palpation or angulation stress
- x-ray - trabeculae cross fracture site, visible callus bridging site

**COMPLICATIONS OF FRACTURES**

Table 3. Complications of Fractures

	Early	Late
Local	neurovascular injury infection compartment syndrome implant failure fracture blisters	malunion nonunion osteonecrosis osteomyelitis heterotopic ossification post-traumatic arthritis reflex sympathetic dystrophy
Systemic	sepsis DVT/PE fat embolus ARDS hemorrhagic shock	

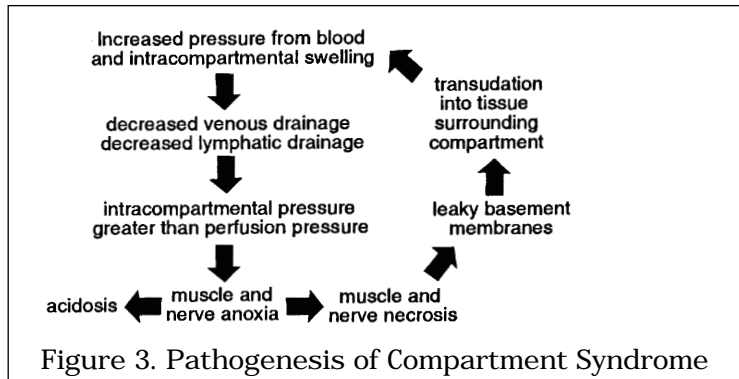
**COMPARTMENT SYNDROME**

- in anatomical "compartments" where muscle and tissue bounded by fascia and bone (fibro-osseous compartment) with little room for expansion (i.e. forearm, calf)
- increased pressure in compartment exceeds capillary perfusion pressure (approximately 30 mmHg) which leads to muscle necrosis and eventually nerve necrosis

Etiology

- fracture, dislocation
- soft tissue damage and muscle swelling
- crush injury
- arterial compromise
- muscle anoxia
- venous obstruction
- increased venous pressure
- constrictive dressing, cast, splint

Pathogenesis



Diagnosis

- classically the tibial compartments
- also in forearm flexor compartment
  - may lead to Volkmann ischemic contracture
- clinical signs
  - pain on passive movement (out of proportion to injury)
  - pain does not respond to normal dose of analgesics
  - pallor
  - paralysis (inability to move limb)
  - pulses are usually still present
  - tense, swollen skin
  - parasthesis
- compartment pressure monitoring
  - in unresponsive or unreliable patients

Table 4. Signs of Compartment Syndrome in Anterior Leg and Forearm

	Anterior leg	Volar forearm
fracture type	tibial fracture	supracondylar (humerus)
weakness	toe, foot extension	finger, wrist flexion
pain	toe, foot flexion	finger, wrist extension
sensory	1st dorsal web space	volar aspect of fingers

Treatment

- remove constrictive dressings
- bivalve casts down to skin and spread open
- place limb at level of heart
- emergency fasciotomy to release compartments if difference between diastolic blood pressure and compartment pressure is less than 30 mmHg (treat within 4-6 hours of onset symptoms)

AVASCULAR NECROSIS

Causes

- steroid use (inflammatory arthritis, IBD, allergies, renal disease, asthma); NOT dose related
- alcohol
- post-traumatic fracture/dislocation
- septic arthritis
- sickle cell disease
- Gaucher's disease
- Caisson's disease - deep sea diving/the bends
- idiopathic

Stage	Clinical Features	X-ray Features
1	preclinical phase of ischemia and necrosis; no pain	no plain x-ray abnormality; may be detectable on MRI
2	painful	early radiographic changes i.e. fragment appears dense, normal bone contour
3	painful	radiographic changes obvious, abnormal bone contour
4	very painful	collapse of articular surface and signs of arthritis on both sides of the joint

**Mechanism**

- occurs following disruption of blood supply to bone
- occurs especially in those bones extensively covered in cartilage which rely on intra-osseous blood supply and distal to proximal blood supply, i.e. head of femur, proximal pole of scaphoid, body of talus
- results in ischemia
- pathologic changes include resorption, subchondral fractures and loss of cartilage

**SHOULDER**

**GENERAL PRINCIPLES**

- shoulder is a complex 4 part joint
  - glenohumeral joint
  - acromioclavicular joint
  - scapulothoracic joint
  - sternoclavicular joint
- examination should involve each of the joints in isolation
- the joint is highly mobile therefore decreased stability
- dislocations and subluxations following trauma are common
- rotator cuff and tendon degeneration are more common than OA
- may be referred pain from C-spine

**PHYSICAL EXAMINATION OF THE SHOULDER**

- LOOK - inspect both shoulders anteriorly and posteriorly, clavicle, deltoids, scapula
  - look for SEADS
- FEEL - for tenderness, swelling, temperature changes, muscle characteristics
  - suprasternal notch --> sternoclavicular joint --> clavicle --> coracoid process --> acromioclavicular articulation --> acromion --> greater tuberosity of humerus --> glenohumeral joint --> bicipital groove
  - spine of scapula, C-spines, axilla (R/O adenopathy, masses)
- MOVE - Active/Passive
  - Active ROM
    - forward flexion and abduction
    - external rotation (elbows at side and flexed 90 degrees, move arms away from midline)
    - internal rotation (with hitchhiker thumb place hands behind small of back and move up back)
  - Passive ROM
    - abduction - 180 degrees
    - adduction - 45 degrees
    - flexion - 180 degrees
    - extension - 45 degrees
    - internal rotation - level of T4
    - external rotation - 40 - 45 degrees



## X-Ray

- radiographic views of the shoulder should include
  - AP, trans-scapular, and axillary views (at least)
  - stress views of the AC joint where indicated
- look for the Mercedes Benz sign (see Figure 4)
  - in the trans-scapular radiograph to look for dislocation
  - humeral head should occupy the circle and be overlapping glenoid

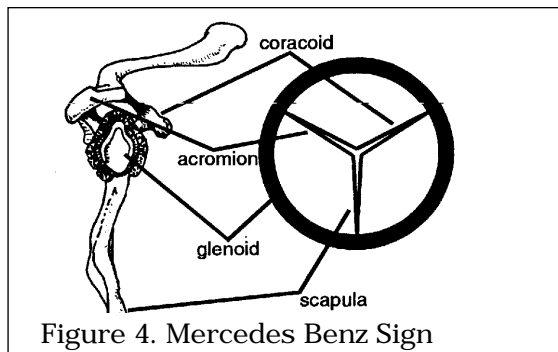


Figure 4. Mercedes Benz Sign

*Adapted with permission from McRae, Clinical Orthopedic Examination, 3rd ed. Churchill Livingstone, New York, 1994.*

## ACROMIOCLAVICULAR JOINT SPRAIN

- AC joint is usually injured after fall onto shoulder with adducted arm
- 2 main ligaments which attach clavicle to scapula
  - acromioclavicular (AC) ligament
  - coracoclavicular (CC) ligament
- acromioclavicular sprains
  - Type I: partial injury, no instability, no displacement
  - Type II: disrupted AC ligament, intact CC ligament
  - Type III: disrupted AC and CC ligaments with superior clavicle displacement
  - Type IV: clavicle displaces superiorly and posteriorly through trapezius
  - Type V: clavicle displaced inferior to acromion or coracoid (beware plexus injury!)
- physical examination
  - palpable step between distal clavicle and acromion
  - pain with adduction (touch opposite shoulder)
- radiographically apparent on stress view (hold weights in hand)
- treat type I or II with ice, immobilization, early ROM and strengthening
- treat type III the same or repair if skin compromise imminent
- operative repair of type IV and V
  - excision of lateral clavicle with reconstruction of CC and AC ligament

## CLAVICULAR FRACTURE

- fall on shoulder or onto outstretched hand
- cosmetically poor but not disabling
- brachial plexus and arterial injuries in 10%
- classified by proximal, middle (most common), or distal third of clavicle
- treatment of proximal and middle third clavicular fractures
  - closed reduction with figure-of-eight brace or sling x 1-2 weeks
  - early ROM and strengthening
- distal third clavicular fractures are unstable and may require ORIF

## ANTERIOR SHOULDER DISLOCATION

- over 90% of all shoulder dislocations, usually traumatic
- may be of two general types:
  - involuntary: traumatic, unidirectional, Bankart lesion, responds to surgery
  - voluntary: atraumatic, multidirectional, bilateral, rehab, surgery is last resort
- occurs when abducted arm is externally rotated or hyperextended
- recurrence rate depends on age of first dislocation
  - at age 20: 80%; at age 21-40: 60-70%; at age 40-60: 40-60%; at age >60: <10%

- associated with Hill-Sachs lesion
  - indentation of humeral head after impaction on glenoid rim
- also associated with Bankart lesion
  - avulsion of capsule when shoulder dislocates
  - associated bony avulsion called "Bony Bankart Lesion"
  - occurs in 85% of all anterior dislocations
- axillary nerve and musculocutaneous nerve at risk
- some associated injuries more common in elderly
  - vascular injury and fracture of greater tuberosity

#### Physical Examination

- "squared off" shoulder
- loss of internal rotation with anteroinferior humeral head
- axillary nerve may be damaged, therefore check sensation and contraction over lateral deltoid; for musculocutaneous nerve check sensation of lateral forearm and contraction of biceps
- apprehension test: for recurrent shoulder instability
  - with patient supine, gently abduct and externally rotate patient's arm to a position where it may easily dislocate. If shoulder is dislocatable, patient will have a look of apprehension on face

#### X-Rays

- humeral head anterior in trans-scapular view
  - humeral head anterior to Mercedes Benz sign
- AP view may show Hill-Sachs lesion if recurrent
- r/o associated humeral neck fracture

#### Treatment

- intravenous sedation and muscle relaxation
- gentle longitudinal traction and countertraction
- +/- alternating internal and external rotation
- Hippocratic Method
  - foot used in axilla for countertraction
- alternatively place patient prone with wrist weight for recurrent dislocator
- sling x 3 weeks with movement of elbow, wrist, fingers
  - rehabilitation aimed at strengthening dynamic stabilizers and avoiding the unstable position (i.e. external rotation and abduction)
- recurrent instability and dislocations may require surgery

### POSTERIOR SHOULDER DISLOCATION

- 5% of all shoulder dislocations
- caused by force applied along the axis of the arm
  - shoulder is adducted, internally rotated and flexed
- the four E's which cause posterior dislocation are:
  - Epileptic seizure
  - Ethanol intoxication
  - Electricity (ECT, Electrocutation)
  - Encephalitis
- often missed due to poor physical exam and radiographs
- if caused by seizure, often bilateral shoulder dislocations

#### Physical Examination

- anterior shoulder flattening, prominent coracoid
- blocked external rotation, limited abduction

#### X-Rays

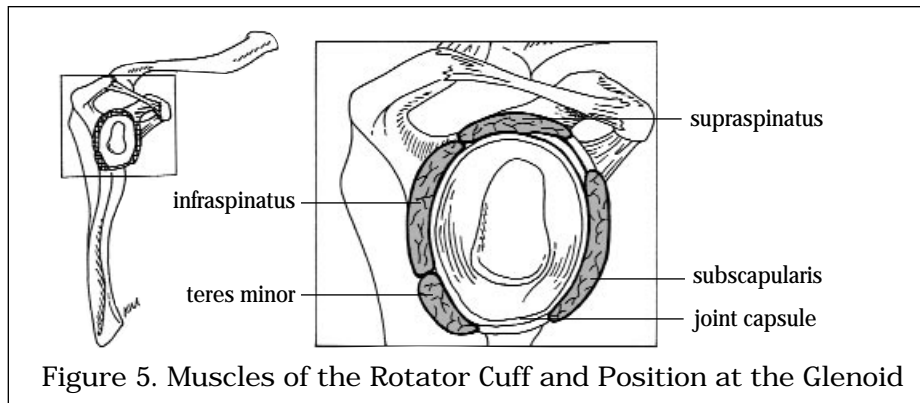
- humeral head posterior in trans-scapular view
  - humeral head posterior to Mercedes Benz sign

#### Treatment

- inferior traction on flexed elbow + pressure on back of humeral head
- may require reduction under GA

### ROTATOR CUFF LESIONS

- the rotator cuff is a sheet of conjoined tendons
  - SITS: Supraspinatus, Infraspinatus, Teres minor, Subscapularis
- stabilizes the head of the humerus in the glenoid, when arm extended or abducted
- about 80% of 80 year olds have rotator cuff lesions



*Drawing by Kevin Millar*

### IMPINGEMENT SYNDROME

- also called "Painful Arc Syndrome"
- describes impingement of supraspinatus tendon between
  - humeral head/greater tuberosity and anatomic arch between anterior edge and undersurface of acromion, AC joint and CA ligament

#### Physical Examination

- painful arc between 90-130 degrees of abduction
- pain on palpation of rotator cuff
- impingement test
  - forward flexion, internal rotation of 90 degree elevated forward flexed arm reproduces pain
  - may have associated osteophytes under acromion or AC joint

#### Types of Impingement Syndrome

- mild ("wear")
  - inflamed rotator cuff
  - aching, reversible, +/- weakness
  - treatment is conservative (physio, NSAIDs)
- moderate ("tear")
  - tendon is thick and fibrotic, microtears
  - night pain and shoulder weakness prominent
  - conservative treatment +/- steroid injection
- severe ("repair")
  - tear of rotator cuff, cannot start abduction
  - may require surgical repair

### FROZEN SHOULDER

- process which involves adhesive capsulitis

#### Primary Adhesive Capsulitis

- idiopathic, usually associated with diabetes mellitus
- may resolve spontaneously in 9-18 months

#### Secondary Adhesive Capsulitis

- due to prolonged immobilization
  - "Shoulder-Hand Syndrome" - hand in cast, immobilized shoulder
  - following MI, stroke, shoulder trauma

#### Treatment

- active and passive ROM (physiotherapy)
- NSAIDs and steroid injections if limited by pain
- MUA (manipulation under anesthesia) or arthroscopy for debridement/decompression
- diabetics usually have poor outcomes

## HUMERAL SHAFT FRACTURE

- ❑ generally treated non-surgically
- ❑ complications include radial nerve injury and nonunion

### Treatment

- ❑ undisplaced fracture +/- radial nerve palsy
  - collar and cuff x 4-6 weeks, then active exercises for shoulder, wrist and hand if fracture united
  - radial nerve palsy usually improves spontaneously over 3-6 months; if no improvement at 3 months than EMG
- ❑ displaced fracture
  - apply collar and cuff or sugar-tong plaster splint cast and reassess radial nerve
  - immobilize 2-3 weeks then go to frontal brace and begin active upper limb exercises
  - ORIF indicated if 1) poor closed reduction, 2) polytrauma, 3) segmental fracture 4) pathologic fracture, 5) neurovascular compromise, 6) associated fracture of proximal ulna "floating elbow"

## PROXIMAL HUMERAL FRACTURE

- ❑ especially common fracture in osteoporotic person
- ❑ fall on outstretched hand
- ❑ fracture involves
  - proximal humeral diaphysis (surgical neck)
  - +/- greater tuberosity
  - +/- lesser tuberosity
- ❑ classify into 2, 3, and 4 part fractures

### Treatment

- ❑ if needed, treat for osteoporosis
- ❑ undisplaced
  - stable/impacted, use Velpeau sling x 1 week then active ROM
  - unstable (unusual), use Velpeau sling x 3 weeks then gentle ROM
- ❑ displaced > 1 cm or angulated > 45°
  - attempt closed reduction, Velpeau sling x 2 weeks, gentle ROM
  - ORIF if unsatisfactory reduction
- ❑ fracture with dislocation of glenohumeral joint
  - high incidence of neurovascular injury and osteonecrosis
  - ORIF; hemiarthroplasty may be necessary

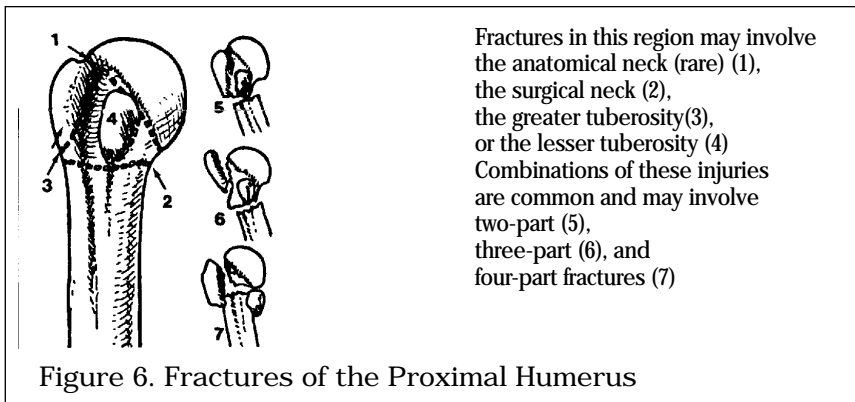
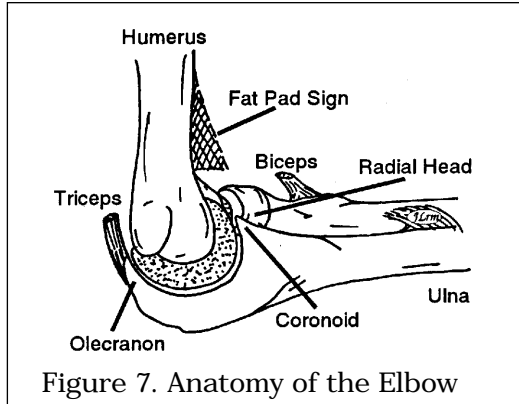
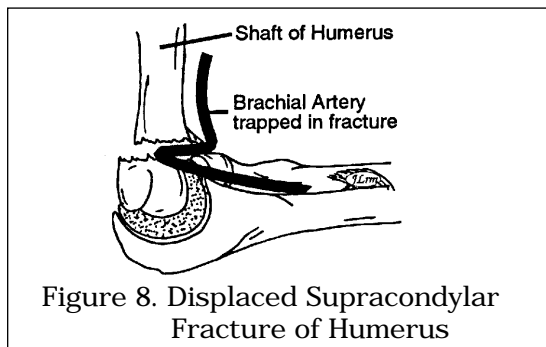


Figure 6. Fractures of the Proximal Humerus

Reproduced with permission from McRae, *Practical Fracture Treatment*, 2nd ed. Churchill Livingstone, New York, 1989.



## SUPRACONDYLAR FRACTURE



- usually in children
- fall on outstretched hand

### Treatment

- children
  - closed reduction +/- percutaneous pinning in OR with fluoroscopy
  - cast in flexion x 3 weeks
- adult
  - undisplaced fracture, may be treated in cast
  - displaced fracture, ORIF since closed reduction usually inadequate

### Complications

- stiffness most common
- see complications of fractures section

## RADIAL HEAD FRACTURE

- mechanism: fall on outstretched arm
- clinically: progressive pain due to hemarthrosis with loss of ROM
- careful, may not be seen radiographically

### Mason Classification

- Type 1: undisplaced segmental fracture, usually normal ROM
- Type 2: displaced segmental fracture, ROM compromised
- Type 3: comminuted fracture
- Type 4: Type 3 with posterior dislocation

### Treatment

- Type 1: elbow slab, sling 3-5 days, early ROM
- Type 2: ORIF radial head
- Type 3/4: excision of radial head +/- prosthesis

**OLECRANON FRACTURE**

- fall on point of elbow with avulsion by triceps or fall on outstretched arm
- active extension absent
- gross displacement can not be reduced closed because of pull of triceps

## Treatment

- undisplaced: above elbow cast 2 weeks, early ROM
- displaced: ORIF, above elbow slab x 1 week, early ROM

**ELBOW DISLOCATION**

- usually young people in sporting events or high speed MVA
- > 90% are posterior or posterior-lateral
- fall on outstretched hand
- r/o concurrent radial head or coronoid process fractures

## Treatment of Posterior Dislocation

- closed reduction: traction then flexion
- above elbow backslab with elbow 90 degrees and wrist pronated
- open reduction if unstable or loose body (unusual)

## Complications

- stiffness
- intra-articular loose body
  - usually from joint surface cartilage
  - not obvious on x-ray
  - occasionally medial epicondyle is pulled into joint, especially in children
- heterotopic ossification (bone formation)
  - prevented by indomethacin
- recurrent dislocation is extremely rare

**FOREARM FRACTURES****GENERAL PRINCIPLES OF FOREARM FRACTURES**

- more commonly fracture of both bones, usually displaced
- if only one bone fractured look for dislocation of other
- forearm fractures in children are usually of the greenstick type, in which only one cortex is involved

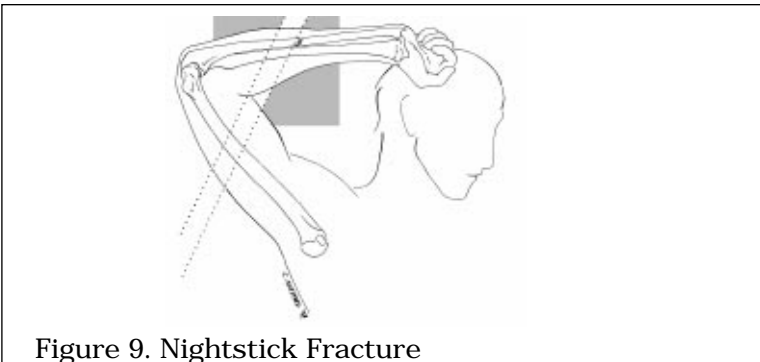
**NIGHTSTICK FRACTURE**

Figure 9. Nightstick Fracture

*Drawing by Chesley Sheppard*

- isolated fracture of ulna, with minimal displacement
- mechanism: from holding arm up to protect face from blow

- r/o radial injury by examining all of radius clinically and radiographically
- treatment: below elbow cast 6 weeks for distal 1/3 fractures
- if angulation or proximal 2/3 severe consider ORIF

## GALEAZZI FRACTURE

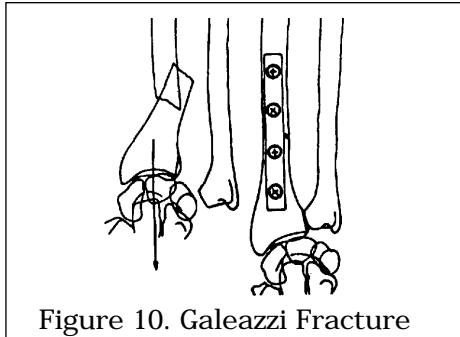


Figure 10. Galeazzi Fracture

*Reproduced with permission from McRae, Practical Fracture Treatment, 2nd ed. Churchill Livingstone, New York, 1989.*

- fracture of distal radius
- dislocation of distal radio-ulnar joint (DRUJ) at wrist
- treatment: immobilize in supination to reduce DRUJ, ORIF

## COMPLICATIONS SPECIFIC TO FOREARM FRACTURES

- cross union - radius malunites to ulna
- loss of pronation/supination
- loss of extension of elbow
- difficult to reduce and maintain closed
  - accurate reduction is essential, usually requires ORIF
- shoulder-hand syndrome

# WRIST

## SCAPHOID FRACTURE

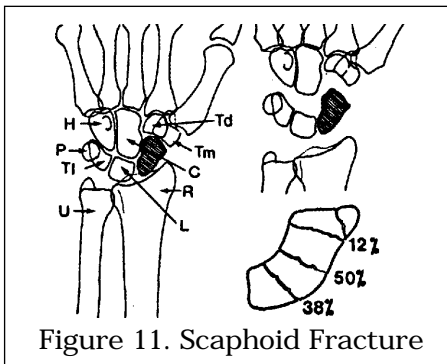


Figure 11. Scaphoid Fracture

*Reproduced with permission from McRae, Practical Fracture Treatment, 2nd ed. Churchill Livingstone, New York, 1989.*

### Etiology

- second most common wrist fracture, common in young adults
- maintain a high index of suspicion with falls on outstretched hand
- blood supply is from distal to proximal poles of scaphoid

### Diagnosis

- clinical
  - pain on wrist movement i.e positive scaphoid test
  - tenderness elicited in anatomical snuff box and over scaphoid tubercle

- ❑ x-ray
  - AP/lateral/scaphoid views required
  - x-ray alone may not reveal scaphoid fracture
  - +/- bone scan and/or CT scan

Treatment

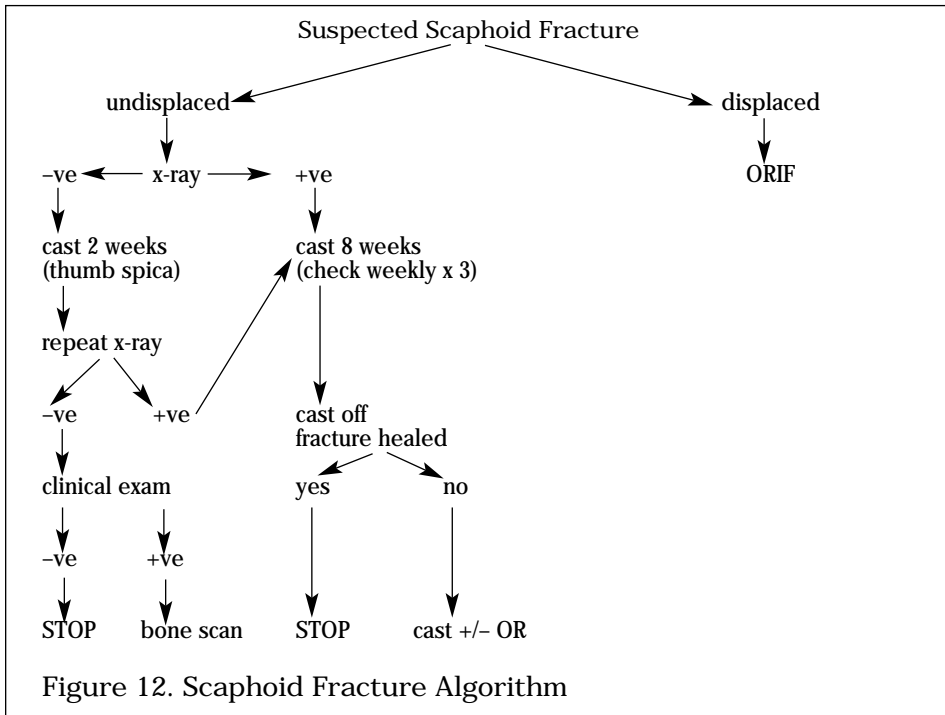


Figure 12. Scaphoid Fracture Algorithm

Complications

- ❑ nonunion +/- AVN
- ❑ highest incidence of AVN (30%) is with fracture of proximal 1/3
- ❑ high incidence of nonunion and AVN with significant displacement

COLLES' FRACTURE

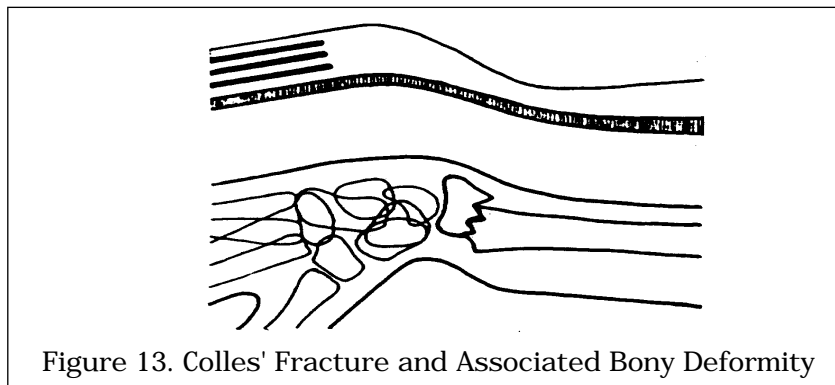


Figure 13. Colles' Fracture and Associated Bony Deformity

*Adapted with permission from McRae, Practical Fracture Treatment, 2nd ed. Churchill Livingstone, New York, 1989.*

Etiology

- ❑ most common wrist fracture
- ❑ fall on outstretched hand
- ❑ most common in osteoporotic bone



Diagnosis

- clinical
  - swelling, ecchymosis, tenderness
  - “dinner fork” deformity
  - assess neurovascular status (carpal tunnel syndrome)
- x-ray: distal fragment is
  1. dorsally displaced with dorsal comminution
  2. dorsally tilted fragment with apex of fracture volar
  3. supinated
  4. radially deviated
  5. shortened (radial styloid normally 1cm distal to ulna)
 +/- fracture of ulnar styloid

Treatment

- if needed, treat for osteoporosis
- nondisplaced
  - short arm cast applied to wrist under gentle traction
  - neutral wrist position
- displaced
  1. anesthesia - hematoma block commonly used
  2. disimpaction - axial traction with increasing force over 2 minutes (pull on thumb and ring finger, with countertraction at the elbow)
  3. reduce by pulling hand into
    - slight flexion
    - full pronation
    - full ulnar deviation
  4. maintain reduction with direct pressure to fracture site, apply well moulded dorsal-radial slab (splint)
  5. post-reduction x-ray (AP/lateral), goal to correct dorsal angulation and regain radial length
  6. check arm after 24 hours for swelling, neurovascular status
  7. circular cast after 1-2 weeks
    - check cast at 1, 2, 6 weeks
    - cast off after 6 weeks, physio (ROM, grip strength)
- if inadequate reduction at any time
  - try closed reduction under GA
  - ORIF

SMITH'S FRACTURE

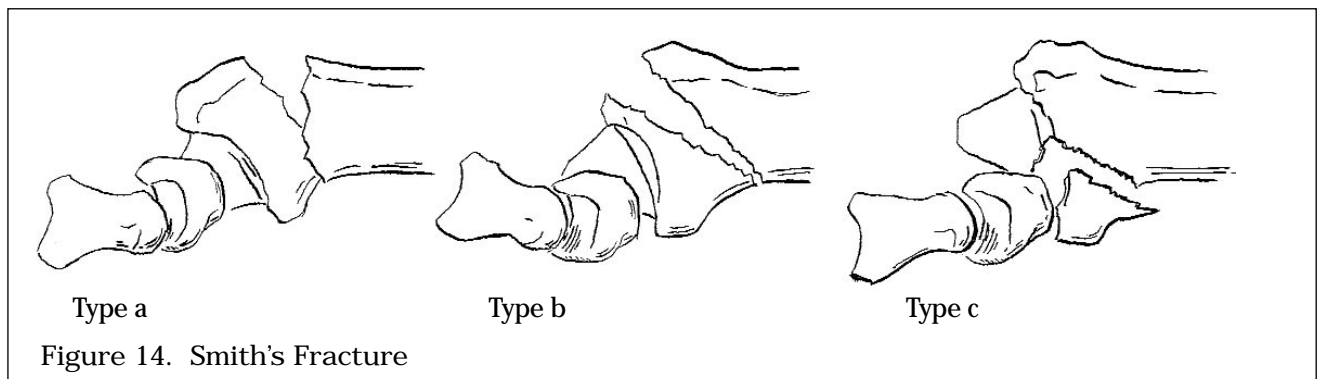


Figure 14. Smith's Fracture

*Drawing by Marc Dryer*

Diagnosis

- clinical presentation and radiographic evidence
- fracture similar to Colles' but volar displacement of distal radius

Treatment

- anesthesia block
- closed reduction in supination and slight flexion
- splint
- ORIF if unstable reduction

## BARTON'S FRACTURE

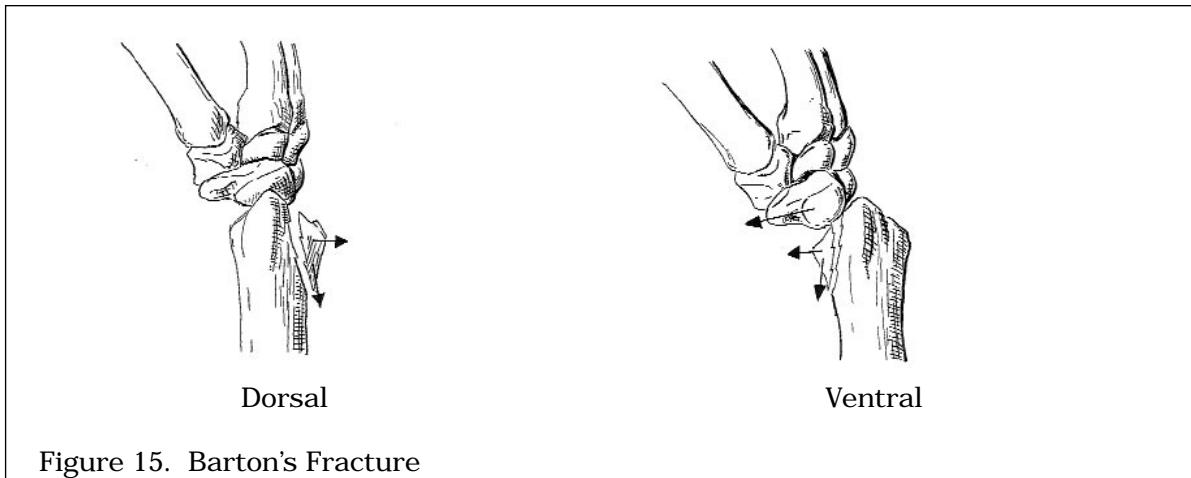


Figure 15. Barton's Fracture

*Drawing by Marc Dryer*

## Diagnosis

- clinical presentation and radiographic evidence
- intraarticular fracture of distal radius resulting from shearing force
- classified as dorsal or volar depending upon location of fragment

## Treatment

- attempt closed reduction although rarely adequate
- dorsal: slight extension, pronation, splint
- volar: slight flexion, supination, splint
- usually requires ORIF if unstable reduction

## Complications of wrist fractures

- most common complications are poor grip strength, stiffness, and radial shortening
- 80% have normal function in 6-12 months
- early
  - difficult reduction +/- loss of reduction
  - compartment syndrome
  - extensor pollicis longus (EPL) tendon rupture
  - acute carpal tunnel syndrome
  - finger swelling with venous or lymphatic block
- late
  - malunion, radial shortening
  - painful wrist secondary to ulnar prominence
  - frozen shoulder ("shoulder hand syndrome")
  - post-traumatic arthritis
  - carpal tunnel syndrome
  - RSD

**DIFFERENTIAL DIAGNOSIS OF BACK PAIN**

- degenerative (90% of all back pain)
  - mechanical (degenerative, facet)
  - spinal stenosis (congenital, osteophyte, central disc)
  - peripheral nerve compression (disc herniation)
- cauda equina syndrome
- neoplastic
  - primary, metastatic
- trauma
  - fracture (compression, distraction, translation, rotation)
- spondyloarthropathies
  - e.g. ankylosing spondylitis
- referred
  - aorta, renal, ureter, pancreas

**Epidemiology**

- common problem
- L4-5 and L5-S1 most common sites
- 10% nerve root compression
- less than 2% results from tumour, trauma, other diseases

**DEGENERATIVE BACK PAIN**

**Pathogenesis**

- loss of vertebral disc height with age results in
  - bulging and tears of annulus fibrosus
  - change in alignment of facet joints
  - osteophyte formation
- pain sensation is transmitted by branches of adjacent nerve root, which innervates disc and facet joints
  - results in both localized pain and referred pain down adjacent spinal nerve
  - radiating pain typically occurs in buttocks and down legs
- pain may originate from disc +/- facet joints
- disc herniations are most commonly posterolateral or lateral
  - posterolateral herniations (common) affect the nerve root below the disc (i.e. the L4-L5 disc compresses L5 root)
  - lateral herniations (rare) affect the nerve root above the disc (i.e. the L4-L5 disc compresses L4 root)
- natural history: 90% improve with conservative treatment within 3 months
- conservative
  - modified activity
  - back strengthening
  - NSAIDs

Table 6. Types of Low Back Pain

	Mechanical Back Pain		Direct Nerve Root Compression	
	Disc Origin	Facet Origin	Spinal Stenosis	Root Compression
pain dominance	back	back	leg	leg
aggravation	flexion	extension standing, walking	exercise, extension walking, standing	flexion
onset	gradual	more sudden	congenital or acquired	acute leg ± back pain
duration	long (wks, months)	shorter (days, wks)	acute or chronic history (weeks to months)	short episode attacks (minutes)
treatment	relief of strain, exercise	relief of strain, exercise	relief of strain, exercise	relief of strain, exercise + surgical decompression if progressive or severe deficit

- ❑ spinal stenosis
  - acquired stenosis best thought of as a progression or end stage degenerative disc disease, in which osteophytic growth results in a narrowed spinal canal

Table 7. Differentiating Claudication

	Neurogenic	Vascular
aggravation	with standing or extension walking distance variable	walking set distance
alleviation	change in position (usually flexion, sitting, lying down)	stopping walking
time	relief in 10 minutes	relief in 2 minutes
character	neurogenic ± neurological deficit	muscular cramping

X-Rays

- ❑ AP, lateral, obliques
- ❑ indicated for new onset back pain (i.e. r/o tumour, congenital deformities)
  - look for "Winking Owl sign" --> signifies tumour invasion of pedicle
- ❑ CT scan/myelography, MRI
  - for spinal stenosis, cauda equina syndrome, disc herniation
- ❑ x-rays not very helpful for chronic degenerative back pain
  - radiographic degeneration does not correlate well with back pain

CAUDA EQUINA SYNDROME

- ❑ most frequent cause is large central disc herniation
- ❑ progressive neurological deficit presenting with
  - saddle anesthesia
  - decreased anal tone and reflex
  - fecal incontinence
  - urinary retention
  - SURGICAL EMERGENCY! will cause permanent urinary/bowel incontinence

Table 8. Lumbar Radiculopathy/Neuropathy

Root	L4	L5	S1
motor	quadriceps tibialis anterior	ankle dorsiflexion great toe extensor hip abductor	ankle plantarflexion
sensory	posteromedial	lateral calf or 1st web space	lateral aspect of foot
reflex	knee reflex	hamstring reflex	ankle reflex
test	limitation of femoral stretch	limitation of straight leg raise	limitation bowstring

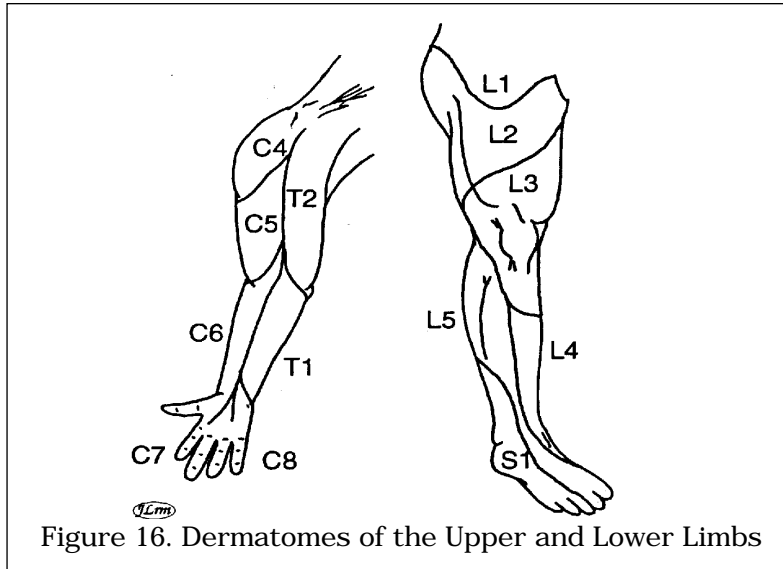


Figure 16. Dermatomes of the Upper and Lower Limbs

TRAUMA

C-Spine X-rays

- can you see C1 to superior portion of T1? - if not, film is INADEQUATE
- should have swimmers view for adequate visualization of C7-T1
- open mouth odontoid view for adequate visualization of atlanto-axial joint
- identify
  - 1) alignment (on lateral films - see Figure 17)
    - anterior body (1)
    - posterior body (2) should curve to anterior foramen magnum
    - facet joints (3)
    - laminar fusion line (4) should curve proximally and point to posterior base of foramen magnum
  - 2) vertebral bodies
    - height and width
  - 3) cartilage
  - 4) soft tissues
    - prevertebral soft tissue: C3=3-5 mm, C7=7-10 mm

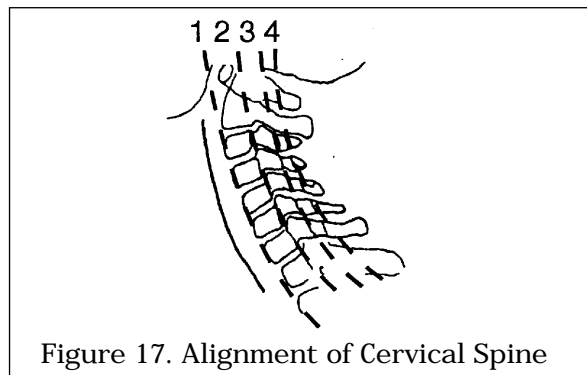
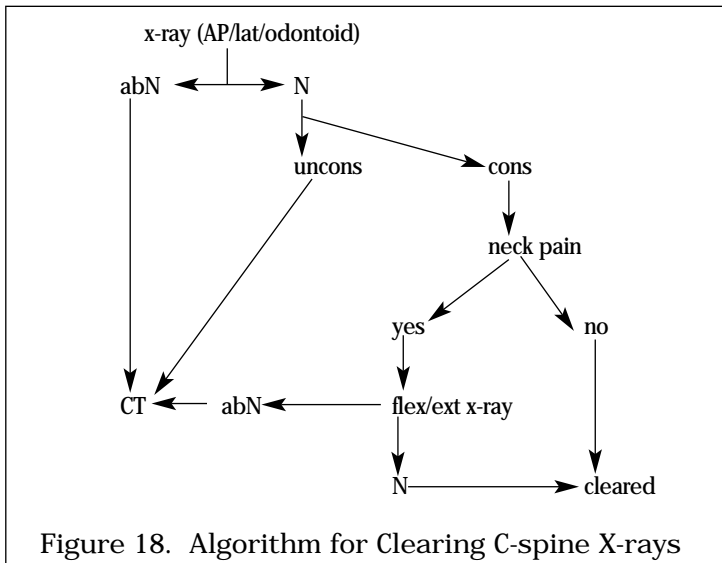


Figure 17. Alignment of Cervical Spine

*Adapted with permission from McRae, Clinical Orthopedic Examination, 3rd ed. Churchill Livingstone, New York, 1994.*

Clearing C-spine X-rays



Root	C5	C6	C7	C8
motor	deltoid supraspinatus biceps	biceps brachioradialis	triceps	digital flexors intrinsic
sensory	axillary nerve (middle deltoid)	thumb and index finger	middle finger	ring and little finger
reflex	biceps middle deltoid	brachioradialis reflex	triceps	finger jerk reflex

THORACIC AND LUMBAR SPINE

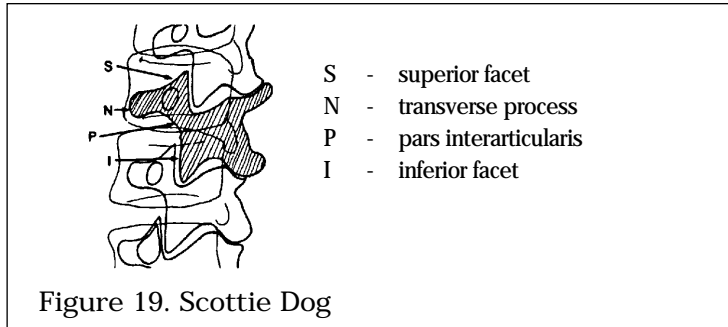
Anterior Column	Middle Column	Posterior Column
anterior longitudinal ligament	posterior longitudinal ligament	posterior body elements
anterior annulus fibrosis	posterior annulus fibrosis	supraspinous, interspinous ligaments
anterior 1/2 of vertebral body	posterior 1/2 of vertebral body	facet joints ligamentum flavum

Etiology

- mechanism of injury
  1. compression: vertical loading leads to failure in anterior column, includes anterior and lateral wedge compression and axial compression ("burst") fracture
  2. distraction: tensile failure in all three columns i.e. Chance fracture
  3. rotation: most serious with high degree of neural damage
- disruption of posterior and middle columns is required for acute instability

X-Ray

- oblique views show "Scottie Dog"
- look for disruption of "Scottie Dog" to identify spondylolysis



Adapted with permission from McRae, *Clinical Orthopedic Examination*, 3rd ed. Churchill Livingstone, New York, 1994.

Treatment

- compression
  - wedge: conservative if < 50% compression
  - burst: may push material into spinal canal therefore surgical correction (distraction and IF for stabilization)
- distraction
  - chance: only bony involvement therefore full healing achieved conservatively
  - soft tissue: surgical stabilization
- rotation
  - burst type: inherently unstable therefore internal stabilization

HIP

DIFFERENTIAL DIAGNOSIS OF HIP PAIN

- traumatic
  - fracture, dislocation
- arthritic
  - septic, degenerative (OA), inflammatory (see Rheumatology Notes)
- referred
  - hip pain is felt in the groin area and anterior thigh
  - spine usually involves buttock and posterior thigh
  - knee, abdominal viscera, vascular (intermittent claudication)
- other
  - AVN of femoral head
  - neoplasm (primary or secondary)

X-Ray Diagnosis

- views: AP, lateral, Judet (oblique) views

Finding	OA	AVN	Hip Fracture
loss of joint space	localized	none	none
subchondral sclerosis	+++ acetabulum and head	++ head only	none
osteophytes	+++	none	none
erosions	none	none	none
leg shortening	+/-	none	+++ if displaced

- Note: AVN becomes same as OA later in disease process, and hip fracture may have preexisting OA

## PELVIC FRACTURES

- ❑ most common fracture involves pubic rami, followed by ilial, ischial, acetabular, coccygeal and sacral bones

Tile Classification (see Figure 20)

- ❑ Type A: stable, minimally displaced, includes avulsion fractures and fractures not involving pelvic ring, e.g. rami fracture
- ❑ Type B: partially unstable, rotationally unstable, but vertically stable, e.g. "open book" fracture from external rotational force to pelvis
- ❑ Type C: unstable, rotationally and vertically unstable, associated with rupture of ipsilateral ligaments, e.g. vertical shear fracture

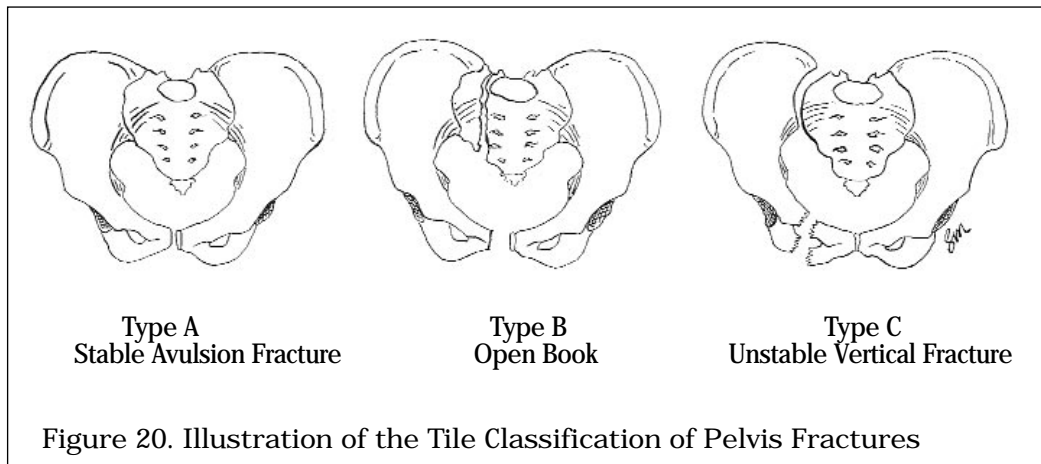


Figure 20. Illustration of the Tile Classification of Pelvis Fractures

*Drawing by Seline McNamee*

### Diagnosis

- ❑ history of injury, high energy trauma
- ❑ examination reveals local swelling, tenderness; if unstable, may have deformity of the hips and instability of pelvis with palpation
- ❑ x-rays (i.e. AP, inlet, and outlet views)

### Treatment

- ❑ ABC's
- ❑ assess GU injury (rectal exam/vaginal exam mandatory)
- ❑ Type A - bedrest and mobilization with walking aids
- ❑ Type B/C - external or internal fixation

### Complications

- ❑ hemorrhage - life threatening
- ❑ bladder/bowel injuries
- ❑ neurological damage
- ❑ obstetrical difficulties
- ❑ persistent sacro-iliac joint pain
- ❑ post-traumatic arthritis of the hip with acetabular fractures

## HIP DISLOCATION

- ❑ mainly seen with artificial hips

### Anterior (rare)

- ❑ blow to knee with hip widely abducted
- ❑ clinically: limb fixed, externally rotated and abducted
- ❑ attempt closed reduction under GA
- ❑ then CT of hip to assess joint congruity

### Posterior

- ❑ severe forces to knee with hip flexed and adducted (e.g. knee into dashboard in MVA)
- ❑ clinically: limb shortened, internally rotated and adducted
- ❑ sciatic nerve injury common



- assess knee, femoral shaft for other injuries/fractures
- +/- fracture of posterior lip of acetabulum or intra-articular fracture
- attempt closed reduction under GA +/- image intensifier
- then CT to assess congruity and acetabular integrity
- traction x 6 weeks, then ROM
- ORIF if unstable, intra-articular fragments, or posterior wall fractures

#### Central

- associated with acetabular fracture

#### Complications

- post-traumatic arthritis due to cartilage injury or intra-articular loose body
- femoral head injury including osteonecrosis + fracture; 100% if > 12 hours before reduction
- sciatic nerve palsy in 25% (10% permanent)
- fracture of femoral shaft or neck
- knee injury (PCL tear with dashboard injury)

## HIP FRACTURE

#### Epidemiology

- common fracture in elderly (greater incidence of osteopenia)
- female > male
- in osteopenic individual, fracture may precede simple fall (muscle stronger than bone)
- in younger individual, fracture related to high energy injury
  - markedly displaced
  - associated with other injuries

#### Diagnosis

- characteristic history, unable to bear weight on affected limb
- limb shortened, externally rotated, painful ROM, antalgic gait
- obtain AP of pelvis and lateral of involved hip
- if findings equivocal - bone scan and tomograms

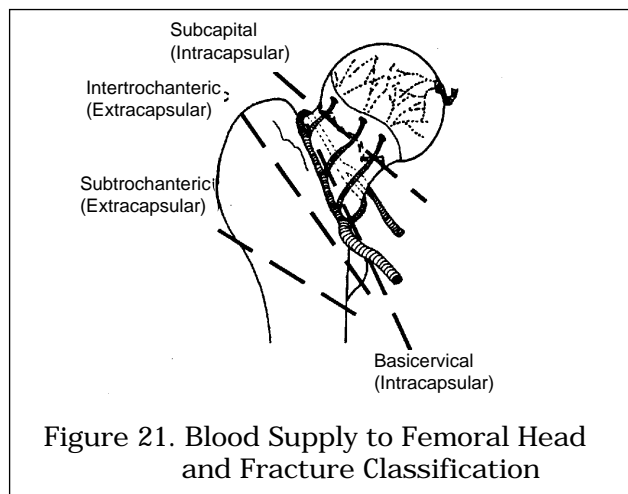


Figure 21. Blood Supply to Femoral Head and Fracture Classification

*Adapted with permission from McRae, Practical Fracture Treatment, 2nd ed. Churchill Livingstone, New York, 1989.*

#### 1. Subcapital Fractures

- fracture between femoral head and intertrochanteric line
- main vascular supply to femoral head from distal arterial ring to proximal head through femoral neck
- fracture interrupts blood supply
  - articular surface restricts blood supply to femoral head
  - AVN risk depends on degree of displacement

Table 12. Garden Classification of Subcapital Fractures

Type	Extent	Displacement	Alignment	Trabeculae
1	Incomplete	Impacted	Valgus	Malaligned
2	Complete	None	Neutral	Aligned
3	Complete	Some	Varus	Malaligned
4	Complete	Marked	Varus	Aligned

## Treatment

- if needed, treat osteoporosis
- restore anatomy, attempt to save head (AVN head CAN heal)
- type of treatment depends on displacement and patient age
- undisplaced (Garden 1,2) - ORIF to prevent displacement
- displaced (Garden 3,4) - depends on patient
  - older patient, poor health --> unipolar hemiarthroplasty
  - younger patient with higher demand lifestyle --> bipolar hemiarthroplasty vs. total hip replacement vs. reduction and internal fixation
  - younger patient with OA of hip --> total hip replacement

## Complications

- AVN
- non-union

## 2. Intertrochanteric Fracture

- extra-capsular fracture, therefore good femoral head viability
- fracture stability determined by amount of compromise to calcar femorale (medial cortex at neck/shaft junction)
- greater and lesser trochanters may be separate fragments
- posterior fragment may be avascular, therefore possible delayed union

## Classification

- 2 part - stable, trochanter intact
- 3 part - one trochanter separated, unstable if large calcar fragment
- 4 part - unstable, both trochanters separated

## Treatment

- ORIF (sliding hip screw) to preserve femoral head

## 3. Subtrochanteric Fracture

- least common hip fracture
- transverse, spiral or oblique fracture passes below lesser trochanter
- younger population with high energy injuries
- x-rays show flexed and abducted proximal fragment, from pull of iliopsoas on lesser trochanter, gluteus medius and minimus on greater trochanter

## Treatment

- usually ORIF
- malunion common

## ARTHRITIS OF THE HIP

- many causes (osteoarthritis, post-traumatic, DDH, RA, etc...)

## Diagnosis

- usually in an older individual
- gradual onset of groin/medial thigh pain, increasing with activity
- limb shortening
- decreased internal rotation/abduction of hip
- fixed flexion deformity
- positive Trendelenburg sign
- x-ray - joint space narrowing, sclerosis, subchondral cysts, osteophytes

## Treatment

- conservative
  - weight loss, walking aids, physiotherapy, NSAID
- surgery
  - realign - osteotomy
  - replace - arthroplasty
  - ablate - arthrodesis, excision

## Trendelenberg Test

- patient stands on affected leg, normally gluteus medius muscle on ipsilateral side contracts to keep pelvis level
- a positive test is if the contralateral side drops or if patient compensates by leaning way over supported leg

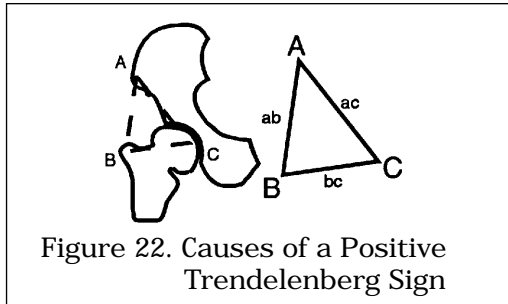


Figure 22. Causes of a Positive Trendelenberg Sign

- may occur anywhere along line "ab"
  - e.g. weak abductors, avulsion of gluteus medius, trochanteric fracture/removal
- may occur anywhere along line "bc"
  - e.g. painful hip due to osteoarthritis, femoral neck in varus, acetabular instability
- may occur anywhere along line "ac"
  - e.g. fractured pelvic side wall

## AVN OF THE FEMORAL HEAD

(see Avascular Necrosis Section)

## Clinical

- sudden onset of severe pain, related to weight-bearing
- worse at night
- rapid progression (compared to OA)

## Diagnosis

- x-ray - r/o hip fracture
- bone scan - see healing fracture
- MRI (best)

## Treatment

- early: vascularized fibular graft to preserve femoral head, rotational osteotomy in young patient with moderate disease
- late: hip replacement

## FEMORAL DIAPHYSIS FRACTURES

- high energy (MVA, fall from height, gunshot wounds)
- low energy (spiral fracture in children)
- high morbidity/mortality (hemorrhage, fat embolism, ARDS, MODS)
- blood replacement often required
- frequently comminuted
- soft tissue trauma

## Clinical

- leg is shortened, externally rotated
- unable to weight bear
- assess neurovascular status
- r/o: open fracture, soft tissue compromise
- r/o: child abuse with spiral fractures in children

## Treatment

- ABCs of trauma are essential
- immobilize leg with Thomas Splint
- adequate analgesia
- surgical fixation (intramedullary nail) within 24 hours
  - high rate of surgical union after 6 to 12 weeks
- early mobilization of hip and knee

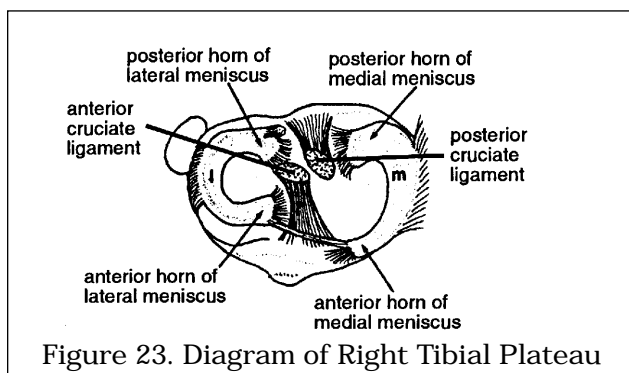
## SUPRACONDYLAR FEMORAL FRACTURE

- high energy, multiple trauma
- knee joint is disrupted severely with bicondylar fracture
- poor prognosis with comminuted fractures
- high incidence of post-traumatic arthritis

## Treatment

- internal fixation and early knee ROM
- quadriceps strengthening

## KNEE



Adapted with permission from McRae, *Clinical Orthopedic Examination*, 3rd ed. Churchill Livingstone, New York, 1994.

## COMMON KNEE SYMPTOMS

- locking = spontaneous block to extension
  - torn meniscus, loose body
- pseudo locking = restricted ROM without mechanical block
  - arthritis (effusion, pain), muscle spasm following injury
- instability = "giving out"
  - torn ACL, patellar subluxation, torn meniscus, loose body
- traumatic knee swelling
  - effusion, usually represents hemarthrosis
  - ligamentous injury with hemarthrosis
  - meniscal injury
  - traumatic synovitis

- non-traumatic knee swelling without trauma
  - septic or crystalline arthritis
  - seronegative arthritis (AS, Reiter's, Psoriatic, IBD)
  - seropositive arthritis (RA, SLE)
  - avascular necrosis
  - sickle cell disease

## EVALUATION OF KNEE COMPLAINTS

### History

- ligament injuries require high energy force
- meniscal injury in young person requires moderate force, while in older person only requires mild force

### Physical Examination

- LOOK: SEADS, alignment
- FEEL: effusion, crepitus
- MOVE: gait, strength, ROM

### Special Tests of the Knee

- Anterior and Posterior Drawer Tests
  - demonstrate torn ACL and PCL, respectively
  - knee flexed at 90 degrees, foot immobilized, hamstrings released
  - if able to sublax tibia anteriorly then ACL may be torn
  - if able to sublax tibia posteriorly then PCL torn
- Lachmann Test
  - demonstrates torn ACL
  - hold knee in 10-20 degrees flexion, stabilizing the femur
  - try to sublax tibia anteriorly on femur
  - similar to anterior drawer test, more reliable
- Posterior Sag Sign
  - demonstrates torn PCL
  - may give a false positive anterior drawer sign
  - flex knees and hips to 90 degrees, hold ankles and knees
  - view from the lateral aspect
  - if one tibia sags posterior than the other its PCL is torn; loss of prominence of tibial tuberosity
- Pivot Shift Sign
  - demonstrates torn ACL
  - start with the knee in extension
  - internally rotate foot, apply valgus force to knee
  - look and feel for anterior sublaxation of lateral tibial condyle
  - slowly flex while palpating knee and feel for pivot which is the tibiofemoral reduction
- Collateral Ligament Stress Test
  - palpate ligament for "opening" of joint space while testing
  - with knee in full extension apply valgus force to test MCL, apply varus force to test LCL
  - repeat tests with knee in 20 degrees flexion to relax joint capsule
  - opening only in 20 degrees flexion due to MCL damage only
  - opening in 20 degrees of flexion and full extension is due to MCL, cruciate, and joint capsule damage
- test for Meniscal tear
  - Crouch Compression test (C2) is most sensitive test
    - joint line pain when squatting
  - McMurray test useful collaborative information
    - with knee in flexion palpate joint line for painful "pop"
    - internally rotate foot, varus stress, and extend knee to test lateral meniscus
    - externally rotate foot, valgus stress, and extend knee to test medial meniscus

### X-Rays of the Knee

- AP standing, lateral
- skyline view
  - with knees in flexion, beam is aimed from anterior tibia to anterior femur
  - allows for view of patellofemoral joint
- obliques for intra-articular fractures

- 3 foot standing view
  - radiograph from hip to foot with patient in standing position
  - useful in evaluating leg length and genu varus / valgus

### LIGAMENTOUS INJURIES OF THE KNEE

- may have hemarthrosis and/or effusion in acute phase
- deceleration or pivoting injury
- must check for effusion and tenderness on physical exam

### ANTERIOR CRUCIATE LIGAMENT TEAR

#### History

- indirect varus blow to knee
- hyperextended knee + internal rotation
- audible pop, knee instability, "giving way"
- immediate swelling
- inability to continue activity

#### Physical

- posterolateral joint line tenderness
- positive Lachmann, pivot shift, anterior drawer,
- effusion, +/- hemarthrosis
  - +/- associated medial meniscus tear, MCL injury (O'Donahue's Unhappy Triad)

#### Treatment

- based on activity and functional impairment
- stable with minimal functional impairment
  - early mobilization
  - physio and quadriceps strengthening
- instability with functional impairment / high demand lifestyle
  - ACL reconstruction

### POSTERIOR CRUCIATE LIGAMENT TEAR

- much less common than ACL injury

#### History

- fall onto flexed knee with plantar flexed foot
- hit anterior tibia on dashboard in motor vehicle accident
- hyperflexion or hyperextension with anterior tibial force

#### Physical

- positive posterior sag sign
- false positive anterior drawer
- true positive posterior drawer

#### Treatment

- conservative vs. surgical PCL reconstruction

### MEDIAL COLLATERAL LIGAMENT TEAR

#### History

- valgus force to knee
- +/- "pop" heard
- severe pain with partial tears
- complete tear may be painless

#### Physical

- swelling
- tender above and below medial joint line
- assess joint space opening with valgus force
  - pain
  - MCL laxity with end point - partial tear
  - absence of end point - complete tear
  - r/o ACL and medial meniscus tear

#### Treatment

- minor
  - immobilize briefly, early ROM and strengthening
- moderate
  - EUA, cast or brace
  - early PT with ROM and strengthening
- severe or combined
  - surgical repair of associated injuries
  - surgical repair of isolated MCL tear is controversial

**LATERAL COLLATERAL LIGAMENT TEAR**

- varus force to knee
- similar history, physical to MCL
- r/o common peroneal nerve injury
- treatment as for MCL

**MENISCAL TEAR**

- medial meniscus torn 8x more than lateral
- 1/2 are traumatic, 1/2 are degenerative
- usually associated with other ligamentous injuries if traumatic

**History**

- twisting force when the knee is partly or completely flexed  
e.g. squatting and then rotating rapidly, skiing, football, tennis
- acute
  - immediate pain, difficulty weight bearing, +/- locking
- chronic
  - pain, swelling, instability

**Physical**

- effusion
- lack of full extension (locking)
- pinpoint joint line tenderness
- McMurray's test

**Diagnosis and Treatment**

- MRI is diagnostic only
- conservative (unless locked)
  - ROM and strengthening exercises
  - NSAIDs
- failed conservative
  - arthroscopy (diagnostic and therapeutic)

**PATELLA/QUADRICEPS TENDON RUPTURE**

- low energy injury, sudden forceful contraction during attempt to stop fall
- partial or complete
- more common in patients with diabetes, SLE, RA, steroid use

**History**

- fall onto flexed knee
- inability to extend knee

**Physical**

- palpable gap between patella and quadriceps
- may have hemarthrosis/ effusion of knee

**Investigations**

- knee radiographs to rule out patellar fracture
- joint aspirate may show hemarthrosis

**Treatment**

- surgical repair of tendon

**DISLOCATED KNEE**

- bad high energy injury
- associated injuries
  - popliteal artery intimal tear or disruption 35-50%
  - capsular, ligamentous and common peroneal nerve injury

**Investigations**

- angiogram

**Treatment**

- closed reduction, above knee cylinder cast x 4 weeks
- alternately, external fixation especially if vascular repair
- surgical repair of all ligaments if high demand patient

## PATELLA DISLOCATION

## Etiology

- commonly seen in young adults
- patella dislocates laterally over flexed knee
- predisposition - weak vastus medialis muscle and tight lateral retinaculum, valgus knees
- can be acute, chronic or recurrent
  - acute occurs with direct blow, excessive muscular forces
  - recurrent type is associated with shallow intercondylar groove or patella alta (high riding patella)
- may have associated osteochondral fracture of anterior lateral femoral condyle or avulsion of medial patella

## Diagnosis

- severe pain
- difficulty extending knee
- positive patellar apprehension sign
  - sublux patella laterally over extended knee
  - pain if subluxation is reproduced, patient apprehensive
- chronic patient reports catching, giving way with walking or turning

## Treatment

- acute - conservative
  - reduce patella
  - gentle ROM
  - strengthen quadriceps, especially vastus medialis
  - support during sports activities
- chronic / recurrent
  - often conservative treatment unsuccessful
  - lateral retinacular release (surgical) plus medial plication
  - tibial tubercle transfer corrects line of force by reinserting patella medially and distally

## CHONDROMALACIA PATELLAE

- also known as patellofemoral syndrome
- commonly seen in young adults, especially females
- softening of articular cartilage, usually medial aspect of patella
- etiologies: malalignment, trauma, congenital abnormal shape of patella or femoral groove, recurrent patellar subluxation or dislocation, excessive knee strain (athletes)

## History

- deep aching anterior knee pain
- exacerbated by prolonged sitting, strenuous athletic activities, stair climbing

## Physical

- pathognomonic: pain with firm compression of patella into medial femoral groove
- tenderness to palpation of underside of medially displaced patella
- patellar inhibition test
- pain with extension against resistance through terminal 30-40 degrees

## X-Rays

- AP, lateral, skyline

## Treatment

- conservative treatment
  - physio (isometric quads strengthening)
  - NSAIDs
- surgical treatment with refractory patients
  - tibial tubercle elevation
  - arthroscopic shaving and debridement and lateral release



## PATELLAR FRACTURE

### History

- direct - blow to patella
- indirect - sudden muscular contraction
- immediate pain

### Physical

- marked tenderness, pain
- patellar deformity
- inability to extend knee
- proximal displacement of patella
- unable to straight leg raise because disruption of extensor mechanism

### X-Ray

- AP, lateral (need to exclude bipartate patella)

### Treatment

- isolated vertical fractures - conservative treatment - plaster cast 6 weeks, early ROM
- transverse displaced fracture - ORIF
- comminuted fracture - ORIF; may require complete or partial patellectomy

## TIBIA

### TIBIAL PLATEAU FRACTURE

- result from femoral condyle(s) being driven into the proximal tibia often due to a valgus or varus force
- lateral > medial

### Treatment

- if depression is < 3 mm
  - long leg cast-brace x 6 weeks, early ROM
  - NWB x 2 months
- if depression > 3 mm, displaced or comminuted
  - ORIF to reconstruct knee joint
  - +/- bone graft to elevate fragment

### TIBIAL DIAPHYSIS FRACTURE

- high intensity injury
  - associated with crush injuries and MVAs
- soft tissue, nerve and vessel injury common
  - assess neurovascular status
  - r/o open fracture
- displacement is difficult to control
- good reduction is required
  - shortening: < 1 cm
  - angulation in varus/valgus plane: < 5 degrees
  - angulation in antero-posterior plane: < 10 degrees
  - rotation neutral to slight external rotation
  - apposition: ≥ 50%
- healing time: 16 weeks on average

### Treatment

- ABCs
- closed injuries = closed reduction
  - long leg cast x 4-6 weeks
  - followed by BK cast until healed
- open injuries
  - ORIF with external fixator
  - wounds on anterior surface heal poorly and may necrose
- unstable injuries or failed closed reduction require IM nail
- high risk of compartment syndrome
  - closed reduction and cast; admit and observe for compartment syndrome surgery; prophylactic fasciotomy if operating on tibia fracture

## EVALUATION OF ANKLE COMPLAINTS

- ☐ history
- ☐ physical examination
  - neurovascular status
  - look, feel, move (dorsiflexion, plantarflexion)
  - assess for tenderness at knee (Maisonneuve), lateral and medial malleoli

## X-ray

- ☐ views
  - AP, Lateral and Mortise (15 degrees internal rotation)
  - Mortise gives true view of talus in tibiotalar joint
    - space between talus ---> tibia and talus ---> fibula
    - space should be symmetric and < 4 mm with no talar tilt
  - disrupted space signifies ligamentous or bony injury
- ☐ when to x-ray - Ottawa ankle rules (*Stiell et al., JAMA, 1994*)
  - ankle x-ray is only required with
    - pain in malleolar zone AND
    - bony tenderness over distal 6 cm of medial or lateral malleolus OR inability to weight bear both immediately and in ER
  - foot x-ray series is only required with
    - pain in midfoot zone AND
    - bony tenderness over navicular or base of fifth metatarsal OR inability to weight bear both immediately and in ER

## ANKLE FRACTURES

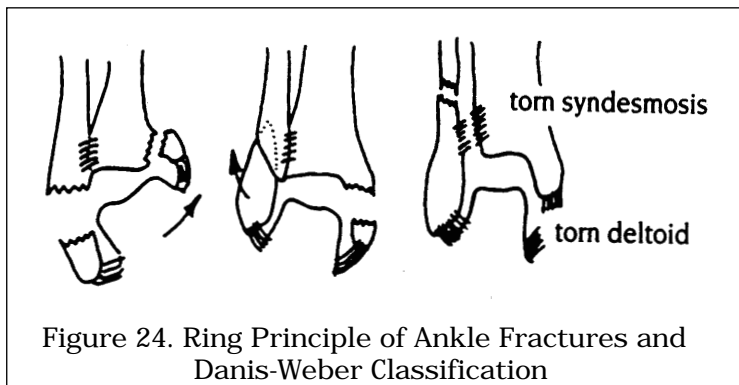


Figure 24. Ring Principle of Ankle Fractures and Danis-Weber Classification

*Adapted with permission from Dandy, Essential Orthopedics and Trauma, 2nd ed. Churchill Livingstone, New York, 1993.*

## Ring Principle of the Ankle

- ☐ the ankle can be thought of as a ring (see Figure 24)
  - a: lateral malleolus
  - b: medial malleolus
  - c: posterior malleolus (posterior medial malleolus)
  - d: deltoid ligament
  - e: syndesmotomic ligament (syndesmosis)
  - f: calcaneofibular ligament
- ☐ fractures of the ankle involve
  - ipsilateral ligamentous tears or bony avulsion
  - contralateral shear fractures
- ☐ pattern of fracture
  - determined by mechanism of injury
  - avulsion fractures are transverse
  - shear fractures are oblique if pure inversion / eversion
  - shear fractures are spiral if rotational force

## Danis-Weber Classification

- ☐ level of fibular fracture relative to tibial plafond
- ☐ Type A (infra-syndesmotomic)
  - pure inversion injury

- avulsion of lateral malleolus below plafond or torn calcaneofibular ligament
- +/- shear fracture of medial malleolus
- ❑ Type B (trans-syndesmotic)
  - external rotation and eversion
  - avulsion of medial malleolus or rupture of deltoid ligament
  - spiral fracture of lateral malleolus starting at plafond
- ❑ Type C (supra-syndesmotic)
  - pure external rotation
  - avulsion of medial malleolus or torn deltoid ligament
  - fibular fracture is above plafond
  - frequently tears syndesmosis
  - Maisonneuve fracture if at proximal fibula
  - posterior malleolus avulsed with posterior tibio-fibular ligament

#### Treatment

- ❑ undisplaced fractures: NWB BK cast
- ❑ displaced fractures: reduction asap
- ❑ indications for ORIF
  - all fracture-dislocations
  - all type C fractures
  - trimalleolar (lateral, medial, posterior) fractures
  - talar shift or tilt
  - failure to achieve or maintain closed reduction
- ❑ prognosis dependent upon anatomic reduction
  - high incidence of post-traumatic arthritis

### LIGAMENTOUS INJURIES

#### Medial Ligament Complex (deltoid ligament)

- ❑ responsible for medial stability
- ❑ usually avulses medial or posterior malleolus
  - posterior malleolus = posterior part of medial malleolus

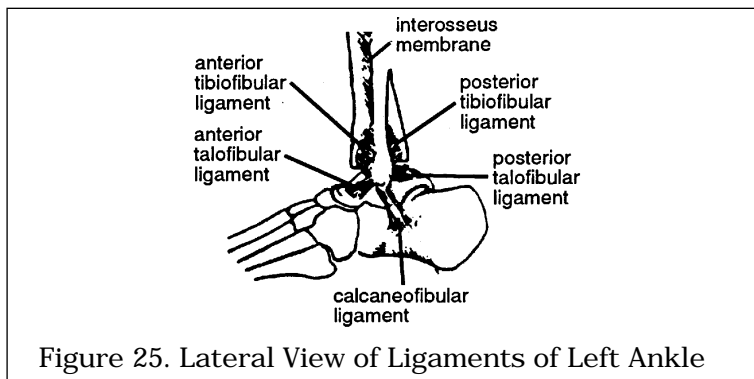


Figure 25. Lateral View of Ligaments of Left Ankle

#### Lateral Ligament Complex (ATFL, CFL, PTFL)

- ❑ responsible for lateral stability
- ❑ clinical: swelling and discoloration
- ❑ diagnosis: stress x-rays and mortise view
  - talar inversion produces joint separation exceeding the unaffected side by six degrees

#### Anterior Talofibular Ligament (ATFL)

- ❑ most common ligamentous ankle injury
- ❑ sprained by inversion and plantar flexion
- ❑ swelling and tenderness anterior to lateral malleolus
- ❑ anterior drawer test for ankle positive with Grade III ATFL injury
  - attempt to subluc talus anteriorly
  - if positive then stress other lateral ligaments
- ❑ inversion stress test for integrity of other ligaments

## Grading and Treatment of Ligamentous Ankle Injuries

- Grade I (ligament sprain)
  - pain
  - RICE (Rest, Ice, Compression, Elevation)
- Grade II (ATFL tear)
  - pain on motion
  - strap ankle in dorsiflexion and eversion
  - no more than 6 weeks, physio for proprioceptive re-training
- Grade III ATFL + CFL tear
  - unstable ankle
  - talar tilt apparent on mortise view
  - BK walking cast x 3 weeks, PT for proprioceptive re-training

## RECURRENT ANKLE SUBLUXATION

- etiology
  - ligamentous laxity
  - internal derangement of anatomy
  - intra-articular loose body
  - joint (loss of normal proprioception)
- treatment depends on cause
  - ligament reconstruction for lateral laxity and talar tilt
  - arthroscopy / arthrotomy for internal derangement
  - strengthening and balance training for neuropathic joint

## FOOT

## TALAR FRACTURE

- 60% of talus covered by articular surface
  - blood supply to talus: distal to proximal
  - fractures of the neck at risk of AVN
- mechanism: MVA or fall from height
  - axial loading or hyper-plantar flexion injury
  - talar neck driven into tibial margin
- r/o potential associated injuries
  - spinal injuries
  - femoral neck fractures
  - tibial plateau fractures

## X-Rays

- AP/lateral films with CT scan or tomograms of talus

## Treatment

- ORIF: to reduce displacement and prevent AVN or non-union

## Complications

- undisplaced: 0-10% risk of AVN
- displaced: 100% risk of AVN

## CALCANEAL FRACTURE

- mechanism is axial loading
- r/o potential associated injuries
  - spinal injuries (10%)
  - femoral neck fractures
  - tibial plateau fractures

## Physical

- heel viewed from behind is wider, shorter, flatter, varus tilt
- may be swollen, with bruising on soles

## X-Rays

- Broden's views (oblique views of subtalar joint)
- Bohler's Angle decreased (normal: 20 - 40 degrees)

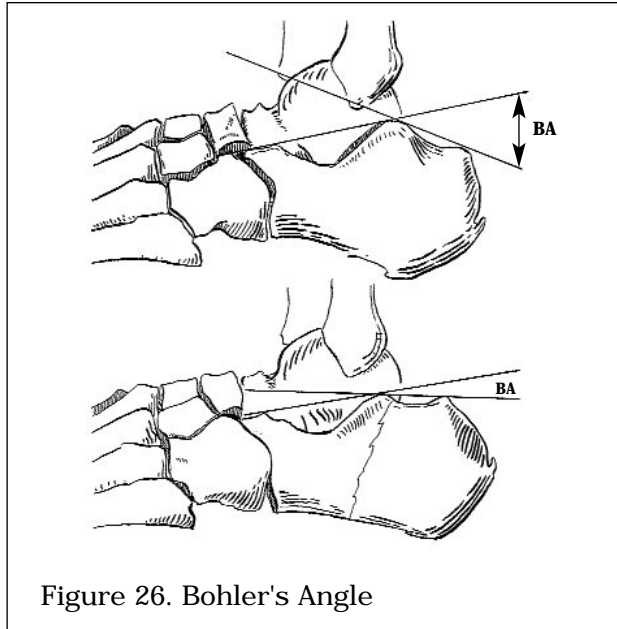


Figure 26. Bohler's Angle

*Drawing by Marc Dryer*

#### Treatment

- goal is to prevent widened heel and maintain subtalar joint congruency
- NWB, early ROM
- ORIF if depressed centrally or tongue-type fracture
- closed vs. open treatment is controversial

#### ACHILLES TENDONITIS

- chronic inflammation from running and shoe-wear (high heels)
- may develop heel bumps (inflammation of superficial bursa overlying lateral insertion of achilles tendon into calcaneus)

#### Diagnosis

- pain, aggravated by passive stretching
- tenderness, swelling
- crepitus on plantar flexion

#### Treatment

- rest, gentle stretching, NSAIDs
- proper footwear +/- orthotics
- do NOT inject steroids (prone to rupture)

#### ACHILLES TENDON RUPTURE

- mid tendon or musculotendinous junction
- spontaneously ruptures
  - during loading activity (e.g. squash, tennis)
  - secondary to steroid injection

#### Diagnosis

- history of pain and inability to walk
- tenderness, palpable gap, weak plantar flexion
- apprehensive to toe-off when walking
- Thompson's Test (patient lying prone)
  - squeezing calf does not passively plantar flex foot

#### Treatment

- low demand or elderly patient
  - cast with foot in plantar flexion
- high demand or young
  - surgical repair vs. cast (controversial)

**PLANTAR FASCIITIS**

- repetitive strain injury of plantar fascia
  - common in runners, jumpers, ballet dancers, obesity
- chronic inflammation due to microtears of plantar fascia

**History**

- intense pain on waking or after rest
- subsides as patient walks
- may be associated with systemic diseases
  - diabetes mellitus
  - enthesopathies including seronegative and positive arthritis

**Physical**

- swelling, local tenderness over plantar fascia
  - mostly at medial calcaneal tubercle
- pain with toe dorsiflexion (stretches plantar fascia)

**X-Ray**

- sometimes show heel spur at insertion of fascia into medial calcaneal tubercle
- NB spur is reactive, not the cause of pain

**Treatment**

- conservative (90% resolve)
  - rest and NSAIDs x 4-6 months
  - steroid injection
  - ultrasound and stretching exercises
  - supportive shoes with heel cup
- surgical in refractory cases  
(must r/o nerve entrapment as cause of pain first)
  - release of plantar fascia
  - 50% effective at pain relief
  - spur removal not required
  - can now be done endoscopically

**BUNIONS**

- two primary causes: hereditary, footwear
- Hallux Valgus
  - may be associated with metatarsus primus varus
  - valgus alignment of MTP joint is aggravated by eccentric pull of EHL and intrinsic
  - secondary exostosis forms with bursa and thick skin creating the bunion

**Treatment**

- treatment is cosmetic and for pain with shoes
- conservative first
  - properly fitted shoes and toe spacer
- surgical
  - removal of bunion with realignment of 1st MTP joint

**METATARSAL FRACTURE**

- as with the hand, 1st, 4th, 5th metatarsals (MT) are relatively mobile, while the 2nd and 3rd are fixed

Fracture	Mechanism	Clinical	Treatment
Avulsion of Base of 5th MT	sudden inversion followed by contraction of peroneus brevis	tender base of 5th MT x-ray foot	requires ORIF if displaced
Jones Fracture midshaft 5th MT	stress injury	painful shaft of 5th MT	NWB BK cast x 6 weeks ORIF if athlete
March Fracture shaft 2nd, 3rd MT	stress injury	painful shaft of 2nd or 3rd MT	symptomatic
1st MT Fracture	trauma	painful 1st MT	ORIF if displaced otherwise NWB BK cast x 3 weeks then walking cast x 2 weeks
Lisfranc Fracture Tarso-MT fracture-dislocation	fall onto plantar flexed foot or direct crush injury	shortened forefoot prominent base	ORIF

## ORTHOPEDIC INFECTIONS

### OSTEOMYELITIS

- bacterial, viral or fungal infection of bone OR bone marrow
- infants, young children, and immunocompromised more susceptible than healthy adults
- infection can be due to direct (trauma, surgery) or hematogenous route
  - *S. aureus* (most common cause of hematogenous route)
  - mixed infection i.e. *Staph*, Enterobacteriaceae, *Pseudomonas* (trauma, post-op, diabetic or IV drug use)
  - *Salmonella* (Sickle Cell Disease)
  - *H. influenzae* (young children)
  - *M. tuberculosis* (affects both sides of joint)

#### History

- asymptomatic (chronic)
- acute sepsis
  - fever, chills, dehydration, lethargy
  - MEDICAL EMERGENCY
- presentation is typically less acute in adults

#### Physical

- febrile
- local tenderness, swelling, heat at metaphysis, decreased joint motion
- neonates
  - pseudoparalysis
  - associated with septic arthritis
- often few signs and symptoms in the adult; usually tender, inflammation

#### Diagnostic Tests

- bloodwork
  - elevated ESR, serial WBC, C-reactive protein
  - blood cultures before antibiotics started (often negative in adults)
- cultures and gram stain from wound or bone biopsy
- x-rays
  - acute: often normal, lucencies appear after 2-4 weeks
  - chronic: onion-skin appearance
- bone scan
  - Indium, Gallium and Technetium show locally increased uptake; Gallium more specific for infection

## Treatment

- blood cultures then start antibiotics empirically
- surgically drain abscesses
- if infection occurs after insertion of prosthesis, often have to remove it

## JOINT INFECTIONS

### SEPTIC ARTHRITIS

- routes of spread
  - hematogenous (most common)
  - direct spread from adjacent infection
  - inoculation

Table 14. Organisms in Septic Arthritis

Age	Organisms	Antibiotic Choice
0-6 months	<i>S. aureus</i> <i>E. coli</i>	Cloxacillin Tobramycin / Gentamycin
6-36 months	<i>S. aureus</i> <i>H. influenzae</i>	Cloxacillin +/- Ampicillin
>36 months	<i>S. aureus</i> streptococci	Cloxacillin +/- Penicillin G
Adults	<i>S. aureus</i> <i>N. gonorrhoeae</i> (especially adults < 30 years)	Cloxacillin ( <i>S. aureus</i> ) Ceftriaxone ( <i>N. gonorrhoeae</i> )

- S. aureus* - most common cause in adults
- N. gonorrhoeae* - can affect multiple joints; if disseminated can have tenosynovitis, skin lesions, young adult males
- M. tuberculosis* - often accompanies bone lesions
- others
  - *B. burgdorferi* (Lyme disease)
  - *S. schenckii* (most common fungal cause)
  - *Salmonella* (Sickle Cell disease)
  - *Pseudomonas* (IV drug use)

## History

- severe pain
- acute sepsis
  - fever, chills, dehydration, lethargy
  - MEDICAL EMERGENCY!

## Physical

- local joint tenderness, swelling, heat
- neonates get pseudoparalysis
- joint held in slight flexion to reduce intra-articular pressure
- unable or unwilling to move joint

## Diagnostic Tests

- blood and throat swab cultures
- joint aspirate for cultures, WBC, Gram stain, ESR, C-reactive protein
- bone scan (hip only)
  - not used to make diagnosis
  - assesses viability of femoral head

## Treatment

- medical: IV fluids and antibiotics, analgesia
- surgical: aspiration or I&D



## Complications

- early
  - septic dislocation
  - AVN femoral head (increased intra-articular pressure due to pus)
- late
  - cartilage and epiphyseal destruction
  - osteomyelitis

## Other Joint Infections

- Reactive Arthritis
  - post infectious
  - most common cause streptococci
  - do not need antibiotics (culture is sterile)
- Viral Arthritis
  - hepatitis B, rubella, mumps, parvovirus B19

# PEDIATRIC ORTHOPEDICS

## FRACTURES IN CHILDREN

- different from fractures in adults
- periosteum is thicker and stronger in children
- type of fracture
  - usually greenstick or buckle because periosteum is intact on one or both sides
  - adults fracture through both cortices
- epiphyseal growth plate
  - plate often mistaken for fracture and vice versa
  - x-ray opposite limb for comparison
- ligamentous injury
  - rarely occur in children
  - mechanism which causes ligamentous injury in adults causes growth plate injury in children
- anatomic reduction
  - gold standard with adults
  - may cause limb length discrepancy in children (overgrowth)
  - accept greater angular deformity in children (remodelling)
  - intra-articular fractures have worse consequences in children because they usually involve the growth plate
- time to heal
  - shorter in children
- always be aware of the possibility of child abuse
  - make sure injury mechanism compatible with injury
  - high index of suspicion, look for other signs, including x-ray evidence of healing fractures at other sites

## EVALUATION OF THE LIMPING CHILD

### History

- always have high suspicion of abuse
- pain, gait
- joint stiffness (especially on waking)
- systemic symptoms
  - fever, rash, fatigue, weight loss, GI symptoms
- past medical and family history

### Physical

#### Basic Screening Tests

- CBC, differential, blood smear, ESR
- radiographs including joint above and below

#### Investigations (based on History and Physical)

- blood tests
  - ANA, RF, complement
  - blood culture
  - CK, APTT, sickle cell prep
  - immunoglobulin electrophoresis

- urinalysis
- synovial fluid analysis for crystals, culture, cytology
- PPD skin test
  - +/- chest x-ray
- slit lamp examination
- diagnostic imaging
  - bone scan
  - gallium scan
  - ultrasound
  - CT / MRI
- bone marrow aspirate

#### Differential Diagnosis

- Congenital
  - developmental/congenital dysplasia of the hip (DDH / CDH)
- Infectious
  - cellulitis
  - necrotizing fasciitis
  - septic arthritis
  - osteomyelitis
- Neoplastic
  - leukemia
  - primary bone tumour
  - neuroblastoma
- Endocrine
  - SH versus GH imbalance in slipped capital femoral epiphysis (SCFE)
  - hypothyroid --> bilateral SCFE
- Trauma
  - joint trauma
  - Legg-Calve-Perthes disease (idiopathic)
  - SCFE
  - Osgood-Schlatter disease
  - patello femoral syndrome
- Vascular/hematologic
  - hemophilia
  - sickle cell anemia
  - Henoch-Schonlein purpura
- Drugs
- Autoimmune
  - juvenile rheumatoid arthritis (JRA)
  - seronegative spondyloarthropathies
  - SLE
  - transient synovitis
- Toxic/metabolic
  - osteochondritis dissecans
- Other
  - abuse
  - hypermobility
  - growing pains
  - psychogenic

#### EPIPHYSEAL INJURY

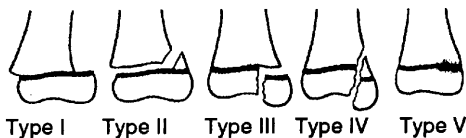


Figure 25. Salter-Harris Classification of Epiphyseal Injury

*Adapted with permission from Dandy, Essential Orthopedics and Trauma, 2nd ed. Churchill Livingstone, New York, 1993.*

## Salter-Harris Classification

- SALT(E)R
- Stable (Type I)
  - transverse through growth plate
- Above (Type II, most common)
  - through metaphysis and along growth plate
- Low (Type III)
  - through epiphysis to plate and along growth plate
- Through (Type IV)
  - through epiphysis and metaphysis
- Ram (Type V)
  - crush injury of growth plate

## Treatment of Epiphyseal Injury

- Type I and II
  - closed reduction and cast immobilization
  - heals well, 95% do not affect growth
- Type III and IV
  - anatomic reduction by ORIF since intra-articular, and also to prevent growth arrest
- Type V
  - high incidence of growth arrest
  - no specific treatment

## PULLED ELBOW

- annular ligament slips between radial head and capitellum
  - follows pull on child's forearm
  - rule out child abuse
- 2-6 years old, due to underdeveloped radial head
- forearm is pronated, painful and "will not move"
  - point tenderness over radial head
  - pseudoparalysis of arm
- radiographs
  - not for diagnosis, but to rule out fracture
- treatment
  - gentle supination while moving from extension to flexion
  - pain relieved and function returns immediately
  - may immobilize x 1 day in sling for comfort

## DEVELOPMENTAL DYSPLASIA OF THE HIP

- formerly called congenital dysplasia of the hip (CDH)
- due to ligamentous laxity and abnormal slope of acetabular roof
- predisposing factors (5F's)
  - Family history, Females (> males), Frank breech, First born, leFt side
- spectrum of conditions
  - dislocated femoral head completely out of acetabulum
  - dislocatable head in socket
  - head subluxes out of joint when provoked
  - dysplastic acetabulum, more shallow and more vertical than normal
- if painful suspect septic dislocation

## Physical

- diagnosis is clinical
- limited abduction of the flexed hip (< 50-60 degrees)
- asymmetry in skin folds and gluteal muscles, wide perineum
- Barlow's test (for dislocatable hip)
  - flex hips and knees to 90 degrees and grasp thigh
  - fully adduct hips, push posteriorly
- Ortolani's test (for dislocated hip)
  - initial position as above but try to reduce hip with fingertips during abduction
  - palpable clunk if reduction is a positive test
- Galleazzi's Sign
  - knees at unequal heights when hips and knees flexed
  - dislocated hip on side of lower knee
- Trendelenburg test and gait useful if older (> 2 years)

## Imaging

- can U/S in first few months to view cartilage
- follow up radiograph after 3 months
- CT scan (rarely done)

## Treatment and Complications

- 0-6 months: Pavlik harness to maintain abduction and flexion
- 6-18 months: adductor tenotomy, traction, hip spica (if Pavlik harness fails)
- > 18 months: open reduction and pelvic osteotomy
- complications
  - redislocation, inadequate reduction, stiffness
  - AVN of femoral head

## LEGG-CALVE-PERTHES DISEASE

- self-limited AVN of femoral head
- etiology unknown, 20% bilateral, males more common
- clinical picture
  - limping child usually 4-10 years old
  - tender over anterior thigh
  - decreased internal rotation, abduction
- diagnosis is clinical
- x-ray may show
  - lateral subluxation of femoral head
  - subchondral fracture
  - metaphyseal cyst
- treat to preserve ROM and preserve femoral head in acetabulum
  - physiotherapy for ROM
  - brace in flexion and abduction x 2-3 years
  - femoral or pelvic osteotomy
- prognosis better in
  - males < 5 years old with < 1/2 head involved
- complicated by early onset OA and decreased ROM

## SLIPPED CAPITAL FEMORAL EPIPHYSIS

- Type I Salter-Harris epiphyseal injury
- most common adolescent hip disorder, peak at 12-15 years
- risk: male, obese, hypothyroid

## Etiology is Multifactorial

- genetic (AD, Blacks > Caucasians)
- mechanical (growth spurt, overweight)
- endocrine (SH vs. GH imbalance)

## History

- limp with medial knee or anterior thigh pain

## Physical

- Whitman's sign: with flexion there is an obligate external rotation of the hip
- restricted internal rotation, abduction, flexion
- pain at extremes of ROM
- tender over joint capsule

## X-Rays

- need AP and frog-leg lateral views
- posterior and medial slip
  - if mild slip, AP view may be normal or slightly widened growth plate compared with opposite side

## Treatment and Complications

- gently reduce with traction, ORIF with pins, crutches and NWB
- complications
  - AVN (most common), chondrolysis, pin penetration, premature OA, chronic loss of ROM

**CONGENITAL TALIPES EQUINOVARUS (CTEV)**

- also known as club foot
- 3 parts to deformity
  - Talipes: talus is plantarflexed and medially rotated
  - Equinus: ankle is plantarflexed
  - Varus: heel and forefoot are in varus (supination)
- may be idiopathic, neurogenic, or syndrome-associated
  - examine hips for associated DDH
  - examine knees for deformity
  - examine back for dysraphism (unfused vertebral bodies)
- 50% bilateral, males = females
- treat by changing cast q 3 weeks
  - correct deformities in order
  - forefoot adduction, ankle inversion, equinus
- surgical release in refractory case (50%)
  - posteromediolateral release of heel cords and capsule
  - delayed until 3-4 months of age

**SCOLIOSIS**

Type	Cause
Idiopathic	most common (90%)
Congenital	vertebrae fail to form or segment
Secondary	leg length discrepancy, muscle spasm
Neuromuscular	UMN or LMN lesion, myopathy
Other	osteochondrodystrophies, neoplastic, traumatic

- age: 10-14 years
- more frequent and more severe in females

**Physical**

- asymmetric shoulder height when bent forward
  - Adam's Test: rib hump when bent forward
- scapulae prominent, flank creased, pelvis asymmetric
- associated posterior midline skin lesions
  - cafe-au-lait spots, dimples, neurofibromas
  - axillary freckling
  - hemangiomas, hair patches
- pelvic obliquity
- associated pes cavus or leg atrophy
- apparent leg length discrepancy

**X-Rays**

- 3 foot standing films
  - use Cobb's method to measure curvature
- may have associated kyphosis

**Treatment Based on Degree of Curvature**

- < 20 degrees: observe for changes
- > 20 degrees or progressive: bracing (many types)
- > 40 degrees, cosmetically unacceptable or respiratory problems
  - require surgical correction

- primary bone tumours are rare after 3rd decade
- metastases to bone are relatively common after 3rd decade

#### Diagnosis

- pain, swelling, tenderness
- routine x-ray - describe by:
  - location (which bone, diaphysis, metaphysis, epiphysis)
  - size
  - involvement (cortex, medulla, soft tissue)
  - radiolucent, radiodense or calcified
  - reaction of surrounding bone (sclerosis, borders)
  - margin
  - any pathological fracture
- malignancy is suggested by rapid growth, warmth, tenderness, lack of sharp definition
- staging should include
  - bloodwork
  - CT chest
  - liver function tests
  - bone scan
- as much information as possible on anatomic extent of tumour (including plain films, tomography, bone scanning, angiography, CT, +/- MRI if necessary) should be obtained prior to biopsy
- should be referred to specialized centre prior to biopsy
- "if you are not going to resect it don't biopsy it"
- classified into benign, benign aggressive, and malignant

### BENIGN BONE TUMOURS

#### 1. Osteoid Osteoma

- age 10-25 years
- small, round radiolucent nidus (< 1 cm) surrounded by dense bone
- tibia and femur; diaphyseal
- produces severe intermittent pain, mostly at night
- characteristically relieved by ASA

#### 2. Osteochondroma

- metaphysis of long bone
- cartilage-capped bony spur on surface of bone ("mushroom" on x-ray)
- may be multiple (hereditary form) - higher risk of malignant change
- generally not painful unless impinging on neurovascular structure
- malignant degeneration occurs in 1-2 %

#### 3. Enchondroma

- age 20-40 years
- 35% occur in the small tubular bones of the hand; others in femur, humerus, ribs
- benign cartilage growth, develops in medullary cavity
- single/multiple enlarged rarefied areas in tubular bones
- lytic lesion with specks of calcification on x-ray

#### 4. Cystic Lesions

- includes unicameral bone cyst, aneurysmal bone cyst, fibrous cortical defect
- children and young adults
- local pain, pathological fracture or accidental detection
- translucent area on metaphyseal side of growth plate
- cortex thinned/expanded; well defined lesion
- treatment of unicameral bone cyst with steroid injections +/- bone graft

#### Treatment

- in general, curettage +/- bone graft

### BENIGN AGGRESSIVE BONE TUMOURS

#### 1. Giant Cell Tumours

- 80% occur > 20 years, average 35 years
- distal femur, proximal tibia, distal radius
- pain and swelling
- cortex appears thinned, expanded; well demarcated sclerotic margin
- 1/3 benign, 1/3 invasive, 1/3 metastasize
- 30% recur within 2 years of surgery

## 2. Osteoblastoma

- aggressive tumour forming osteoid
- lesions > 2 cm in size and grow rapidly
- painful
- most frequent in spine and long bones (humerus, femur, tibia)

## Treatment

- controversial, should do metastatic work up
- wide local excision +/- bone graft

## MALIGNANT BONE TUMOURS

## 1. Osteosarcoma

- bimodal age distribution
  - ages 10-20 (60%)
  - > 50 with history of Paget's disease
- invasive, variable histology; frequent metastases
- predilection for distal femur (45%), tibia (20%) and proximal humerus (15%)
- history of trauma common
- painful, tender, poorly defined swelling
- x-ray shows Codman's Triangle: characteristic periosteal elevation and spicule formation representing tumour extension into periosteum with calcification
- treatment with complete resection (limb salvage, rarely amputation) adjuvant chemo, radiotherapy

## 2. Chondrosarcoma

- primary: previous normal bone, patient over 40; expands to give pain/pathological, fracture flecks of calcification
- secondary: malignant degeneration of preexisting cartilage tumour such as enchondroma or osteochondroma
- occurs in pelvis, femur, ribs, shoulder
- x-ray shows large exostosis with calcification in cap
- highly resistant to chemotherapy, treat with aggressive excision

## 3. Ewing's Sarcoma

- thought to arise from bone marrow vascular endothelium
- florid periosteal reaction in diaphysis of long bone; ages 10-20
- present with mild fever, anemia, leukocytosis and elevated ESR
- moth-eaten appearance with periosteal "onion-skinning"
- metastases frequent
- treatment: chemotherapy, resection, radiation

## 4. Multiple Myeloma

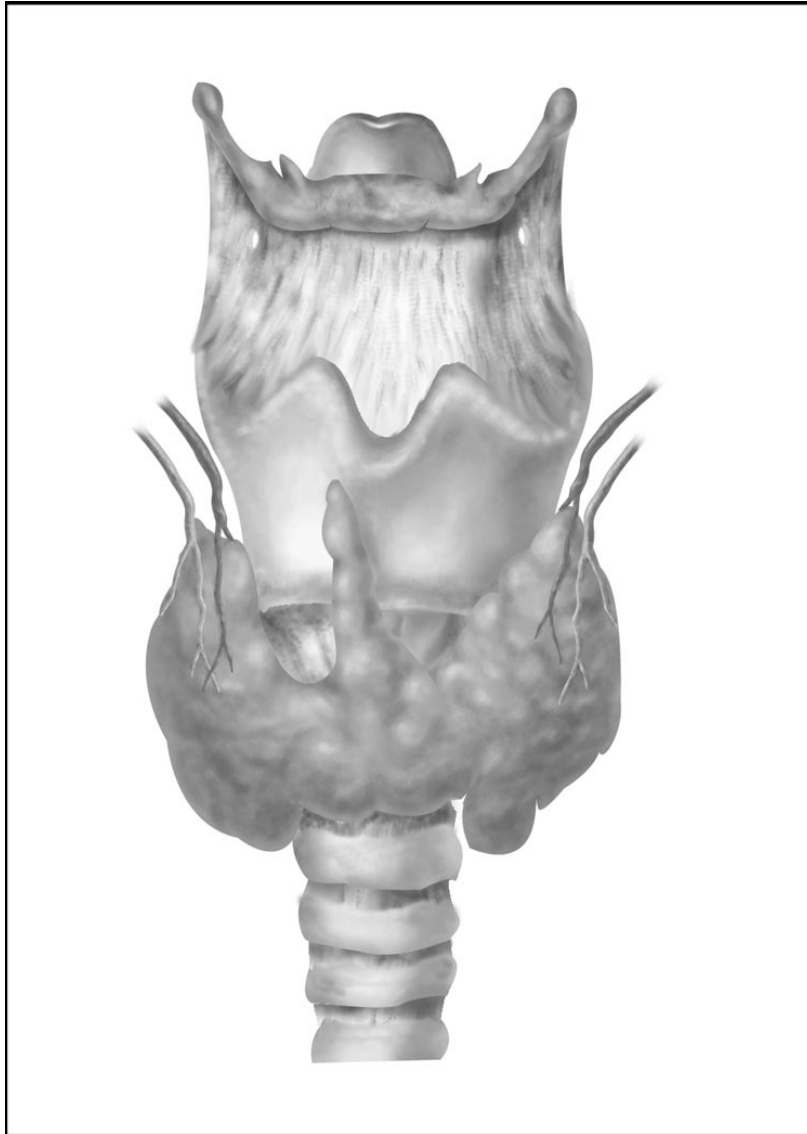
- most common primary malignant tumour of bone in adults
- anemia, anorexia, renal failure, nephritis, ESR elevated
- osteoporosis, punched out lesions, compression fracture
- weakness, bone pain
- diagnosis
  - serum/urine protein electrophoresis
  - bone marrow aspirate

## 5. Bone Metastases

- PT Bamum Loves Kids
- 2/3 from Breast or Prostate
- also consider Thyroid, Lung, Kidney
- usually osteolytic; prostate occasionally osteoblastic
- bone scan may be helpful

## Treatment (for 4 and 5)

- stabilization of impending fractures
  - internal fixation
  - IM rods
  - bone cement



*Drawing by V. Mazurco*