Objectives:

After studying the summary of RCC the student should be able to:
1. Describe the urologic evaluation of a 50-year-old female with gross, painless hematuria.
2. Give a differential diagnosis of a solid mass lesion (seen on ultrasound) arising from one kidney.
3. State the TNM staging system for renal cell carcinoma.
4. State two situations where a partial nephrectomy may be considered instead of a radical nephrectomy for a solid renal.

Introduction:

1. **Renal cell carcinoma (RCC) represents approximately 90% of all primary renal malignancies in adults and 3% of all adult cancers. It is characterized by a lack of early warning signs, diverse clinical manifestations, and resistance to radiation and chemotherapy.**
2. Other primary renal malignancies include transitional cell carcinoma (TCC) (arising from the urothelium of the calyces or renal pelvis), oncocytoma, sarcomas (various types), Wilm's tumour, carcinoid and lymphoma. **Other than RCC, TCC and oncocytoma, the other renal malignancies are extremely rare in adults.**
3. Angiomyolipoma is frequently mentioned as a renal tumour but it is better described as a hamartoma (a focal malformation that resembles a neoplasm; composed of an abnormal mixture of tissue elements, or an abnormal proportion of a single element, normally present in that site, which develop and grow at virtually the same rate as normal components). It is a benign lesion comprised of smooth muscle cells, blood vessels and adipocytes. It can be diagnosed by CT scan, which demonstrates fat within the lesion (fat is very low density on CT scan - negative Hounsfield units). Multiple, bilateral renal angiomyolipomas are seen in patients with Tuberous Sclerosis.

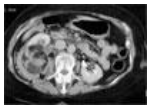

Ct of an Angiomyolipoma
Fat containing mass (arrows) arising from mid portion right kidney
(note residual parenchyma(curved arrows)).

Angiomyolipma of the superior pole of the kidney - Gross pathology

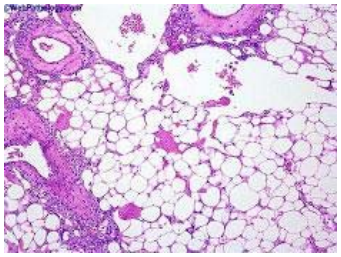

Angiomyolipoma - Microscopic pathology
Microscopically, angiomyolipomas are composed of variable amounts of adipose tissue, smooth muscle, and thick-walled blood vessels

4. Hemangiopericytoma (a.k.a. juxtaglomerular tumour) is a very rare, benign, renin-secreting tumour, which may be suspected in patients with severe hypertension.
5. Oncocytoma is a primary renal tumour of very low malignant potential and is frequently placed in the list of "benign" renal tumours in textbooks. This is somewhat controversial as local recurrence and multifocality are described (rarely) following surgical excision. The prognosis after surgical excision of an oncocytoma is excellent.

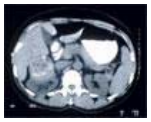

Ct of an Oncocytoma of the right kidney

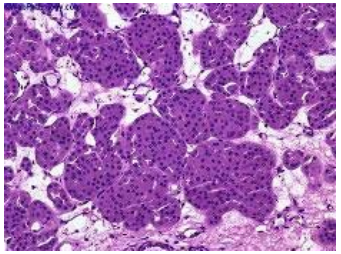

Oncocytoma - Microscopic pathology
The classic histologic pattern of oncocytoma consists of nested or organoid arrangement of
tumor cells surrounded by moderate to abundant quantity of myxoid or hyalinized stroma.

Pathology:

1. The cell of origin in RCC is the proximal tubular cell.
2. The great majority of cases occur in a "sporadic" form but hereditary or familial forms of RCC do exist. The best known form of hereditary RCC is von Hippel-Lindau syndrome, which is characterized by: autosomal dominant inheritance with RCC, bilateral (as opposed to unilateral in the sporadic form), pheochromocytoma, CNS hemangioblastomas, retinal angiomas, pancreatic cysts, islet cell tumours and epididymal cystadenomas.
3. The risk factors for sporadic RCC are not known.
4. The male: female ratio is 2:1.
5. Cigarette smokers have a 2X greater risk of RCC than non-smokers.
6. Patients with renal failure (from any cause) have an increasing likelihood of developing RCC the longer they stay on dialysis. The RCC in dialysis patients rarely develops before 5 years of dialysis and is always seen with multiple cysts in the kidneys (termed "acquired cystic disease of dialysis"). It is not known whether the risk of RCC diminishes after renal transplant.
7. RCC are vascular tumours that tend to spread either by direct invasion through the renal capsule into perinephric fat and adjacent visceral structures or by direct extension into the renal vein and inferior vena cava. The most common site of metastases is the lung. Other frequent sites of disease spread include: liver bone, ipsilateral adjacent lymph nodes, adrenal gland, and the opposite kidney.

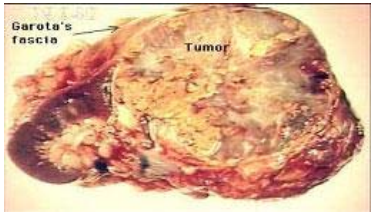

Radical nephrectomy - contents of Gerota's fascia (kidney, perirenal fat, adrenal)

RCC - Gross pathology
Here is a renal cell carcinoma that on sectioning is mainly cystic with extensive hemorrhage.

RCC of the lower pole - Gross pathology
This renal cell carcinoma demonstrates distortion and displacement of the renal parenchyma by the tumor mass in the lower pole. This malignant neoplasm is variegated on cut surface, with yellow to white to red to brown areas.

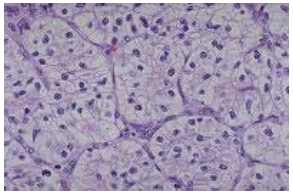

RCC - microscopic pathology
This is the classic histologic appearance of a renal cell carcinoma: the neoplastic cells have clear cytoplasm and are arranged in nests with intervening blood vessels. This appearance is why they are often called "clear cell carcinomas".

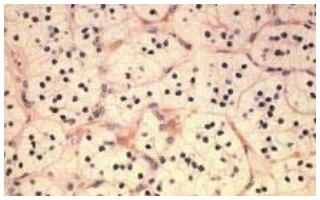

Granular Cell RCC - Microscopic pathology
Granular cell type contains cells that have large nuclei that stain darker than the clear cell variety and the cytoplasm tend to be more grey to white

Clinical Findings:

1. RCC typically remains asymptomatic until it has become locally extensive or metastatic.
2. It is becoming increasingly common that RCC is found "incidentally" on abdominal CT scans or ultrasounds that are ordered for unrelated reasons. Currently, about 2/3 of RCC is diagnosed incidentally.
3. Approximately 1/3 of cases of RCC are diagnosed following a presenting complaint. The frequencies of presenting symptoms, when present, are shown below:

A) Gross hematuria 40%
B) Flank pain 40%
C) Palpable flank mass 25%
D) Classic triad (above 3) 10%
E) Right-sided varicocoele <2% (due to occluded IVC/gonadal vein)

4. 1/3 of symptomatic patients have evidence of metastatic disease on presentation. Symptoms secondary to metastatic disease include: dyspnea and cough (lung mets), seizures and headache (brain mets), or bone pain (bone mets)
5. Poor prognostic indicators as they usually indicate metastases include: weight loss, weakness, anemia, bone pain.
6. RCC is well known for the associated paraneoplastic syndromes and has been termed the "internist's tumour". The following is a list (in decreasing order of occurrence) of various associated abnormalities:

A) Elevated ESR
B) Hypertension (renin mediated)
C) Anemia
D) Weight loss/ cachexia
E) Fever of unknown origin
F) Elevated liver transaminases (called "Stauffers' syndrome")
G) Hypercalcemia (PTH-like hormone)
H) Polycythemia (erythropoietin)
· These abnormalities do not necessarily indicate metastatic disease. Rather, they more likely indicate elaboration of biologically active hormones/cytokines from the primary tumour.

Imaging and Investigations:

1. If a solid renal mass is seen on ultrasound then a CT scan with and without IV contrast is
required. If the patient cannot receive standard IV contrast then an MRI with and without IV gadolinium is an acceptable alternative. The ultrasound is not accurate enough to properly stage the tumour. CT is the modality of choice for staging RCC.
2. A typical finding of RCC on CT is a non-cystic mass that becomes enhanced with the use of IV contrast media, absence of fat and a normal collecting system (i.e.: not TCC of the renal pelvis). In general, RCC exhibits an overall decreased density in Hounsfield units compared with the normal renal parenchyma but shows a heterogeneous pattern of enhancement or increased attenuation (slightly decreased from surrounding parenchyma) when contrast is used. Other important features to note on the CT scan are the size of the lesion, any invasion of perirenal fat, adrenal gland or surrounding structures, any invasion of the renal vein or IVC, any suspicious retroperitoneal lymphadenopathy, any liver metastases and the size and normality of the opposite kidney.

3. Appropriate studies for complete clinical evaluation include:

A) History and physical examination,
B) CBC
C) Serum chemistries (renal and hepatic function)
D) Urinalysis
E) Chest X-ray
F) CT scan of abdomen and pelvis

4. Optional studies ordered when indicated by signs and symptoms:

A) Chest CT when equivocal findings on CXR
B) Radionuclide bone scans with X-rays of abnormal areas
C) Head CT

TNM Staging for RCC
T1 < 7cm, confined to the kidney
T2 > 7 cm, confined to the kidney
T3a invades adrenal or perirenal fat but not beyond Gerota's fascia
T3b tumour thrombus in the renal vein or IVC below the diaphragm
T3c tumour thrombus in the IVC above the diaphragm
T4 invades adjacent organs or retroperitoneal structures

N1 metastases to a single regional lymph node

N2 metastases to more than one regional lymph node

M1 distant metastases (lung most common)

Treatment:

1. **Surgical resection is the only curative therapy for RCC. RCC is highly resistant to chemotherapy and radiotherapy. Partial responses are occasionally seen with immunotherapy.** Approximately 1/3 of patients have metastatic disease at presentation and there is no effective therapy. A careful evaluation is required to rule out metastatic disease before surgery. In addition to the abdominal CT scan, a chest CT scan is often done at the same time. A bone scan is done if the serum calcium is elevated or if symptoms suggest bone involvement. A head CT scan is done if symptoms warrant.
2. **Radical nephrectomy** refers to complete removal of the contents of Gerota's fascia (the kidney, perirenal fat and the adrenal gland). The upper ureter is divided and the middle and distal portions of the ureter are left in-situ.

· Regional lymphadenectomy is advocated by some surgeons but grossly positive lymph nodes carry a very poor prognosis whether lymphadenectomy is performed or not.
· Removal of the ipsilateral adrenal gland is controversial but it should be included with the specimen for large tumours (>7 cm), upper pole tumours and tumours that appear close on the CT scan.
· The operation is usually performed through a flank incision but it may be done through a midline incision or even laparoscopically.
· Resection of IVC tumour thrombus is technically possible but may require veno-veno by-pass or cardiac by-pass. Therefore, such an operation can only be done in very specialized centres. Some patients with IVC thrombus will also have metastatic disease and would not be candidates for this kind of surgery.

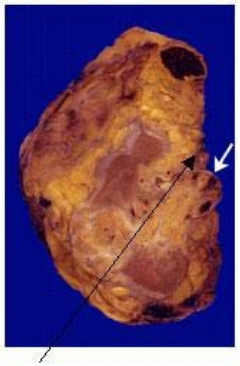

Tumour invading renal vein

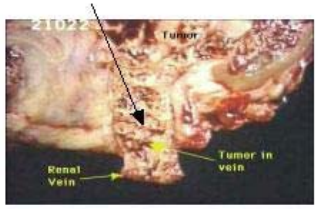

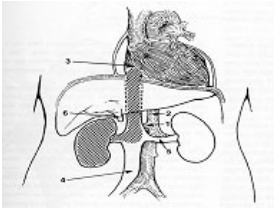

RCC with IVC extension

3. **Partial nephrectomy** may be considered in certain circumstances such as bilateral RCC, RCC in
a solitary kidney, pre-existing renal impairment or a small tumour (<4 cm).

· When a small tumour is resected with a clear margin of normal kidney around it, the cure rate for partial nephrectomy is equivalent to radical nephrectomy.
· If the opposite kidney is normal, the safest operation to do is a radical nephrectomy.

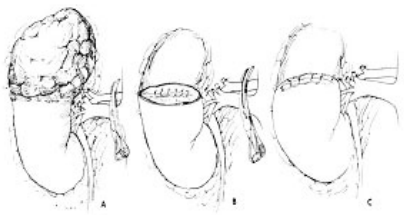

Partial nephrectomy

4. Nephrectomy may be considered for palliative reasons in patients with metastatic disease who
experience refractory hematuria, flank pain or disabling paraneoplastic syndromes. Often some
palliation can be obtained by angio-infarction of the kidney thus avoiding a major operation.
Consideration may be given to nephrectomy if there is low volume metastatic disease that might
itself be surgically resectable (usually a single lung metastasis).
5. **Chemotherapy and radiotherapy are highly ineffective for RCC. Immunotherapies with interferon-alpha and IL-2 have shown partial response rates of 10% - 20% but long-term survivors with metastatic RCC are extremely rare.**

The New England
Journal of Medicine

Graph from NEJM illustrating partial response to immunotherapy

Five year disease-specific survival (following most effective treatment)

T1 95%
T2 90%
T3a 60%
T3b, c 25-50% (following complete removal of IVC thrombus)
T4 20%

N1, 2 10% - 20%

M1 0%
· Stage at diagnosis is the single most important predictor of survival