

# RHEUMATOLOGY

Dr. R. Shupak and Dr. L. Perlin  
Hazel Oon and Michael Lewis, editors  
Markku Nousiainen, associate editor

MECHANISMS OF RHEUMATIC DISEASE . . . . . 2	SERONEGATIVE RHEUMATIC DISEASES. . . 21
Immune Mechanisms of Disease	Ankylosing Spondylitis
Immunogenetics and Disease	Reactive Arthritis (Reiter's Syndrome)
Psoriatic Arthritis	Inflammatory Bowel Disease
APPROACH TO DIAGNOSIS OF . . . . . 3	CRYSTAL INDUCED ARTHROPATHIES . . . 24
RHEUMATIC DISEASES	Gout
History	Pseudogout (Chondrocalcinosis)
Examination	SEPTIC ARTHRITIS . . . . . 26
Investigations	NON-ARTICULAR RHEUMATISM . . . . . 26
Synovial Fluid Analysis	Fibromyalgia
Radiology	Polymyalgia Rheumatica
DEGENERATIVE ARTHRITIS:. . . . . 7	ARTHROPATHIES:. . . . . 28
OSTEOARTHRITIS	COMMON SITES OF INVOLVEMENT
SEROPOSITIVE RHEUMATIC DISEASES: . . . . . 9	
CONNECTIVE TISSUE DISORDERS	
Rheumatoid Arthritis	
Systemic Lupus Erythematosus	
Antiphospholipid Antibody Syndrome	
Scleroderma/Progressive Systemic Sclerosis	
Polymyositis/Dermatomyositis	
Mixed Connective Tissue Disease	
Sjögren's Syndrome	
SEROPOSITIVE RHEUMATIC DISEASES: . . . . . 18	
VASCULITIDES	
Cutaneous (Hypersensitivity) Vasculitis	
Wegener's Granulomatosis	
Polyarteritis Nodosa	
Microscopic Polyangiitis	
Giant Cell Arteritis (Temporal Arteritis)	
Other Vasculitides	

### IMMUNE MECHANISMS FOR DISEASE

- ❑ many rheumatological conditions are characterized by abnormal types or amounts of serum immunoglobulins/antibodies
- ❑ antibodies function by binding their ligand (antigen) and destroying it
- ❑ antibody production is normally under control of T suppressor lymphocytes
- ❑ immune mediated disease may represent a failure of T-cell suppressor function leading to production of abnormal antibodies
- ❑ antibodies can cause disease by two main mechanisms
  1. cytotoxic mechanism (a type II immune reaction)
    - antibodies are formed against inappropriate targets (e.g. normal tissues)
  2. immune complex mechanism (a type III immune reaction)
    - antibody-antigen complexes are formed and deposit in tissues
- ❑ inflammatory response is initiated
  - complement is activated
  - leukocytes are recruited
  - cells coated with antibody are destroyed
  - cell functions are altered

### IMMUNOGENETICS AND DISEASE

- ❑ cell surface molecules called human leukocyte antigen (HLA) or major histocompatibility complex (MHC) play a role in mediating immune reactions
- ❑ the genes that encode HLAs are on chromosome 6
- ❑ there are three classes of MHC

MHC Class	Types	Location	Function
I	HLA-A, -B, -C	all cells	recognized by CD8+ (cytotoxic) T lymphocytes
II	HLA-DP, -DQ, -DR	antigen presenting cells (mononuclear phagocytes, B lymphs, others)	recognized by CD4+ (helper) T lymphocytes
III	complement components	in plasma	chemotaxis, opsonization, lysis of bacteria and cells

### HLA and Disease

- ❑ individuals with certain HLA types may have increased risk of certain immune mediated disease
- ❑ mechanism is not well understood
- ❑ may be due to
  - molecular mimicry
  - effects on T-cell development
  - inheritance with other pathogenic alleles
  - spurious correlations

HLA Type	Associated Conditions	Comments
B27	ankylosing spondylitis Reiter's syndrome psoriatic arthritis IBD arthropathy (spine)	in AS relative risk = 70-90 in Reiter's RR = 40 psoriatic also associated with B38
DR4, DR1	rheumatoid arthritis	93% of patients have HLA type
DR3	Sjögren's syndrome SLE rheumatoid arthritis	DR3 associated with many non-rheumatic conditions (celiac, IDDM, Grave's, chronic active hepatitis)

Table 1. Classification of Arthritis

<p>Seropositive rheumatic diseases</p> <ol style="list-style-type: none"> <li>1. connective tissue diseases <ul style="list-style-type: none"> <li>rheumatoid arthritis (RA)</li> <li>systemic lupus erythematosus (SLE)</li> <li>antiphospholipid antibody syndrome (APS)</li> <li>scleroderma/progressive systemic sclerosis (PSS)</li> <li>polymyositis (PMY)/dermatomyositis (DMY)</li> <li>mixed connective tissue disease (MCTD)</li> <li>Sjögren's syndrome</li> </ul> </li> <li>2. vasculitides <ul style="list-style-type: none"> <li>polyarteritis nodosa (PAN)</li> <li>microscopic polyangiitis</li> <li>Wegener's granulomatosis</li> <li>hypersensitivity vasculitis</li> <li>giant cell arteritis</li> </ul> </li> </ol> <p>Seronegative rheumatic diseases</p> <ul style="list-style-type: none"> <li>ankylosing spondylitis (AS)</li> <li>reactive arthritis (Reiter's syndrome)</li> <li>psoriatic arthritis</li> <li>inflammatory bowel disease (IBD)</li> </ul> <p>Crystal-induced</p> <ul style="list-style-type: none"> <li>gout (monosodium urate)</li> <li>pseudogout (CPPD)</li> <li>hydroxyapatite deposition disease</li> </ul> <p>Septic/infectious</p> <p>Degenerative</p> <p>Non-articular rheumatism</p>
---

## HISTORY

### Symptoms of Joint Disease

- pain, swelling, function of joint
- extra-articular features
  - consider skin, kidneys, eyes, lungs, GI
  - seropositives --> multisystem
  - seronegatives --> uveitis, urethritis, dactylitis, rash
  - crystalline --> tophi, renal involvement
  - infectious --> site of infection, constitutional symptoms
  - non-articular --> trigger points, dermatographism
- general medical considerations, infections, medication
- pain is often the most prominent symptom and must be characterized with respect to pattern, onset, course, characteristics
- activities of daily living (ADLs)

### Pattern of Joint Involvement

- symmetrical small joint polyarthritis
  - affects wrist, MCP, ankle, MTP
  - e.g. seropositive, psoriatic, tophaceous gout
- symmetrical large joint polyarthritis
  - affects shoulder, hip
  - e.g. RA, AS, polymyalgia rheumatica
- asymmetrical oligoarthritis
  - affects knee, ankle, MTP
  - e.g. seronegative, crystal-induced, infectious

- monoarthritis (elbow, wrist, hip, knee, ankle, MTP)
  - infectious
    - bacterial (neisserial and non-gonococcal)
    - mycobacterial
    - viral
    - Lyme disease
  - crystal-induced
    - gout
    - CPPD
    - hydroxyapatite
  - traumatic
  - hemarthrosis
  - psoriatic arthritis
  - reactive arthritis
  - bacterial endocarditis

### Onset/Duration

- acute (hours)
  - e.g. gout, infectious, palindromic RA
- subacute (days)
  - e.g. pseudogout, infectious
- insidious (months)
  - e.g. degenerative, inflammatory

### Course

- intermittent with return to baseline
  - e.g. gout
- gradual progression over time with acute exacerbation's
  - e.g. pseudogout
- wax and wane with slow progression over time
  - e.g. RA

### Characteristics of Pain

- inflammatory
  - morning stiffness (> 30 minutes)
  - worse after rest
  - signs of acute inflammation: rubor, tumour, calor, dolor
- non-inflammatory/degenerative
  - no or minimal morning stiffness (< 30 minutes)
  - worse with use
  - swelling but usually no heat

## EXAMINATION

### Inspection "Look"

- note involved/active joints
- signs of inflammation, redness, swelling
- alignment (e.g. valgus, varus)
- other changes, nodes, nodules, skin changes, muscle atrophy

### Palpation "Feel"

- warmth, tenderness, effusion
- crepitus, laxity/instability

### Range of Motion "Move"

- assess active, passive
- stress pain

## INVESTIGATIONS

### Bloodwork

- general - CBC, BUN, creatinine
- acute phase reactants - ESR, complement C3 and C4, fibrinogen, serum proteins, alpha-2, gamma globulin, CRP, albumin
- serology - autoantibodies

Table 2. Autoantibodies in Rheumatic Diseases

Autoantibody	Disease	Normals	Comments
RF	RA 80% Sjögren's 50%	< 5%	Levels correlate with disease severity in RA
ANA	SLE 95% other CTDs (e.g. RA, PSS)	< 5%	Sensitive but not specific for SLE
Anti-dsDNA	SLE 30-70%	0%	Levels correlate with disease activity
Anti-Sm	SLE < 30%	0%	Specific but not sensitive for SLE
Anti-Ro (SSA)	Sjögren's 75% SLE 25 %	0.5%	Subacute cutaneous LE and mothers of babies with neonatal lupus
Anti-La (SSB)	Sjögren's 40% SLE 10%	0%	Usually occurs with anti-Ro
Antiphospholipid antibodies (LAC, ACLA)	APS SLE 31-40%	5%	By definition present in APS Only small subset of SLE patients develop clinical syndrome of APS
Anti-histone	Drug-induced SLE > 90% idiopathic SLE > 50%		
Anti-RNP	MCTD	0%	By definition present in MCTD
Anti-centromere	CREST > 80%	0%	
Anti-topoisomerase 70	PSS 26-76%	0%	
c-ANCA	Active Wegener's > 90%	0%	Specific and sensitive
p-ANCA	Wegener's 10%, other vasculitis	0%	Nonspecific and poor sensitivity
Anti-Jo-1 and anti-Mi-2	Polymyositis, dermatomyositis 10-30%	0%	

### Rheumatoid Factor (RF)

- IgM antibodies directed against Fc domain of IgG
- not specific for RA, 5% of healthy people are positive (10-20% over age 65), increased in Hep B, SLE, Sjögren's syndrome, many other conditions
- nephelometry, latex fixation or sheep red cell agglutination tests determine dilution at which patient's serum has detectable antibody (1:80 suspicious, 1:160 is positive)

### Antinuclear Antibodies (ANA)

- antibodies directed against nuclear components (DNA, RNA, histones, centromere, Sm)
- LE cell prep-indirect test of ANA
  - LE cells are PMNs that have phagocytosed extruded nuclei of other cells
  - nucleus extrusion is due to ANAs
  - typical of SLE, seen in RA, PSS, DMY, infections
- fluorescent ANA test
  - fluorescent markers bind ANA
  - SLE shows rim or homogeneous pattern; PSS, RA, and MCTD show speckled
- antiDNA Ab test
  - Abs are directed against single stranded (ss) or double stranded (ds) DNA
  - lupus characterized by anti-dsDNA Abs
  - crithidia test is specific for dsDNA

### Antibodies Against Clotting Factors

- present in SLE
- tested by anticoagulant activities; PTT, INR

### Antibodies Against Erythrocytes

- tested by hemoglobin level, Coombs' test, reticulocyte count, leukocyte count and platelet count

### Antigen-Antibody (Ag-Ab) Complexes

- can detect them with the following tests
  1. serum complement assay to look for low C3 and C4 level
  2. lupus band test on tissue biopsy
    - immunofluorescent Ab against IgG and C3 at the dermal-epidermal junction
  3. light microscopy to look for ragocyte, which is a PMN that has engulfed Ag-Ab complexes

### SYNOVIAL FLUID ANALYSIS

- synovial fluid is an ultrafiltrate of plasma and hyaluronate; it lubricates joint surfaces and nourishes articular cartilage
- analysis provides definitive diagnosis for infectious and crystal disease

### Normal Synovial Fluid

- colourless or straw-coloured
- [protein] = 1/3 of plasma
- albumin/globulin = 4:1
- negative pressure in joint

### Three Most Important Tests of Synovial Fluid (SF) are:

(The Three C's)

- Cell count and differential
- Crystal examination
- Culture and Gram stain

### Gross Appearance

- volume, colour, clarity, viscosity

### Microscopy

- total and differential leukocyte count
- cytology exam, Gram and special stains
- crystals exam
  - gout (monosodium urate)
    - needle-shaped
    - negatively birefringent
    - yellow when parallel to axis of red compensator (by definition)
    - urate crystals
  - pseudogout (calcium pyrophosphate dehydrogenase)
    - rhomboid shaped
    - positively birefringent = blue when parallel to axis of red compensator (by definition)

### Microbiology

- bacterial, mycobacterial and fungal cultures
- antimicrobial sensitivities

### Chemical Tests

- protein, glucose, LDH (less helpful than cell count)

### Immunology

- complement levels
- Ig concentration
- RF, ANA, immune complexes, bacterial antigens and cryoglobulins

### String (SINK) Test For Viscosity (obsolete)

- normal viscous fluid forms string of 3-5 cm
- less stringing indicates inflammation present

### Mucin Clot Test (obsolete)

- 5% acetic acid normally causes formation of stable hyaluronoprotein clot
- inflammatory synovial fluid does not form stable clot

Table 3. Synovial Fluid Analysis

	Normal	Non-Inflammatory	Inflammatory	Infectious	Hemorrhagic
colour	clear	clear	opaque	opaque	sanguinous
viscosity	high (due to hyaluronate)	high	low	low	variable
WBC / mm <sup>3</sup>	< 200	< 2000	> 2000	> 50 000	variable
%PMN	< 25%	< 25%	> 25%	> 50%	variable
examples		traumatic osteoarthritis neuropathic hypertrophic arthropathy	seropositives seronegatives crystal arthropathies	septic arthritis	trauma hemophilia

### RADIOLOGY

- inflammatory
  - diffuse erosion
- non-inflammatory
  - local cartilage loss, decreased joint space, bony overgrowth, eburnation (bony erosion)

## DEGENERATIVE ARTHRITIS: OSTEOARTHRITIS (OA)

### Epidemiology

- most common arthropathy
- increased prevalence with increasing age (35% of 30 years old, 85% of 80 years old)

### Pathogenesis

- genetic predisposition
- abnormal physical forces leading to altered joint function and damage

### Pathology

- primary event is deterioration of articular cartilage
  - loss of proteoglycans and water exposes underlying bone
- abnormal local bone metabolism further damages joint
  - subchondral sclerosis
  - osteonecrosis and cyst formation
  - bone grows beyond joint margin = osteophytes
- synovitis is secondary to cartilage damage

### Classification

- Primary
  - most common
  - etiology unknown; likely genetic predisposition
- Secondary
  - post-traumatic or mechanical
  - post-inflammatory (e.g. RA) or infectious
  - heritable skeletal disorders (e.g. scoliosis)
  - metabolic disorders (e.g. gout, pseudogout, hemochromatosis, acromegaly)
  - neuropathic (also known as Charcot joints)
    - atypical joint trauma d/t loss of proprioceptive senses (e.g. diabetes, syphilis)
  - avascular necrosis (e.g. fracture, steroids, alcohol, gout, sickle cell)
  - other (e.g. congenital malformation)

### Clinical Features

- over age 40
- signs and symptoms localized to affected joints (not a systemic disease)

- pain is often insidious and gradually progresses over years
- flare-ups and remissions may occur
- pain with motion, relieved with rest
- short duration of stiffness (< 1/2 hour) after immobility
- deformity (angulation) and limited motion may occur late
- periarticular muscle atrophy
- locked joint due to "joint mouse" (loose piece of bone in joint)

### Joint Involvement

- any joint can be affected
- shoulder, elbow, wrist and ankle are less common sites
- hand
  - DIP (Heberden's nodes)
  - PIP (Bouchard's nodes)
  - CMC (usually thumb)
  - MCP is often spared

### Clinical Pearl

- OA of MCP joints can be seen in hemochromatosis or chondrocalcinosis

- hip
  - groin pain, internal rotation is lost first
- knee
  - narrowing of one compartment of the knee is the rule (compared to RA)
- foot
  - common in first MTP
- lumbar spine
  - very common especially L4-L5, L5-S1
  - degeneration of fibrocartilaginous intervertebral discs and facet joints, possibly with disc herniation or listhesis (slippage)
  - reactive bone growth can contribute to neurological impingement
  - sciatica (disc protrusion or posterior osteophytes)
  - neurological claudication (spinal stenosis)
- cervical spine
  - common, especially in lower cervical area
  - neck pain

### Laboratory Results

- lab results are normal in OA whereas in inflammatory conditions they are abnormal
- blood
  - normal CBC and ESR
  - negative RF and ANA
- synovial fluid
  - viscous
  - cell count > normal but < 1000
  - normal glucose and protein levels
  - rarely acute inflammation with crystals
- radiology (4 classic findings)
  - narrowing of joint space (uni-compartmental)
  - bony erosions and cysts
  - subchondral sclerosis: "seagull sign"
  - osteophytes

### Management

- presently no treatment alters the natural history of OA
- conservative treatment
  - weight loss
  - rest
  - physiotherapy
  - occupational therapy (aids, splints)
- medical treatment
  - analgesic agents e.g. acetaminophen
  - NSAIDS for secondary inflammation
  - intra-articular injections of hyaluronin compounds (e.g. Synvisc)
  - intra-articular corticosteroids occasionally useful for inflammatory component (maximum 3 injections per year)
- surgical treatment
  - osteotomy, total/partial joint replacement, fusion, joint debridement



Table 4. Features of Seropositive Arthropathies

Clinical Features	Rheumatoid Arthritis	Systemic Lupus Erythematosus	Scleroderma	Dermatomyositis
History	symmetrical polyarthritis (small joint involvement) AM stiffness (>1hr)	multisystem disease - rash, photosensitivity, Raynaud's, alopecia, cardiac and pulmonary serositis, CNS symptoms, glomerulonephritis	Raynaud's, stiffness of fingers, skin tightness, heartburn/dysphagia	heliotrope rash (eye lids), Gottron's papules, macular erythema and poikiloderma (shoulders, neck and chest), proximal muscle weakness +/- pain
Physical Examination	effusive joints tenosynovitis nodules bone-on-bone crepitus	confirm historical findings (typically small joints) +/- effusive joints (can be minimal, look for soft tissue swelling)	skin tightness on dorsum of hand, facial skin tightening, telangectasia, calcinosis, non-effusive joint	rash, proximal muscle weakness
Laboratory				
non-specific	increased ESR in 50-60% increased platelets decreased Hb decreased WBC (Felty's)	increased ESR decreased platelets decreased Hb (autoimmune) decreased WBC (leukopenia, lymphopenia)	increased ESR increased platelets decreased Hb normal WBC	increased ESR normal platelets decreased Hb normal WBC
specific	RF+ ~80%	ANA+ in 95% anti-SM + in 30% anti-dsDNA + in 50-60% decreased C3, C4, total hemolytic complement false positive VDRL (in lupus subtypes) increased PTT (in lupus subtypes; eg. antiphospholipid Ab)	ANA+ in > 90% anti-topoisomerase 70 (diffuse) anti-centromere (usually in CREST)	CPK elevated in 80% ANA+ in 33% anti-Jo-1, anti-Mi-2 muscle biopsy-key for diagnosis EMG
synovial fluid	inflammation leukocytosis (> 10,000)	mild inflammation with + ANA	not specific	not specific
radiographs	demineralization joint space narrowing erosions of subchondral bone absence of bone repair	generally nondestructive/nonerosive +/- osteoporosis +/- soft tissue swelling	+/- pulmonary fibrosis +/- esophageal dysmotility +/- calcinosis	+/- esophageal dysmotility +/- interstitial lung disease

## RHEUMATOID ARTHRITIS (RA)

- chronic, symmetric, erosive synovitis
- characterized by a number of extra-articular features

### Epidemiology

- incidence 0.6-2.9 per 1000 population
- F:M ratio 3:1
- age of onset 20-40
- genetic predisposition: HLA DR4/DR1 association

### Pathogenesis

- hallmark of RA is hypertrophy of the synovial membrane
  - outgrowth of granulation tissue (pannus) into and over the articular surface results in destruction of articular cartilage and subchondral bone
- initiating event unknown, but appears to involve antigenic uptake by macrophages
- two possible pathways (Figure 1)
  1. antigenic processing and presentation to T-cells, resulting in B-cell proliferation and eventual cartilage and bone destruction
  2. IL-1 secretion by macrophages, resulting in synovial cell, chondrocyte and blood vessel proliferation, which also result in cartilage and bone destruction
- the proposed pathways can act independently or simultaneously in the pathogenesis of RA
- two theories which attempt to explain chronic remissions and exacerbations seen in RA
  1. sequestered Ag
    - during inflammation, ICs are deposited at cartilage-bone junction, which is an avascular area --> ICs remain free of reticulo-endothelial system but are released as further cartilage breaks down --> triggering cascade

### 2. molecular mimicry

- cartilage damage --> altered configuration of cartilage resembles the offending agent --> triggering cascade

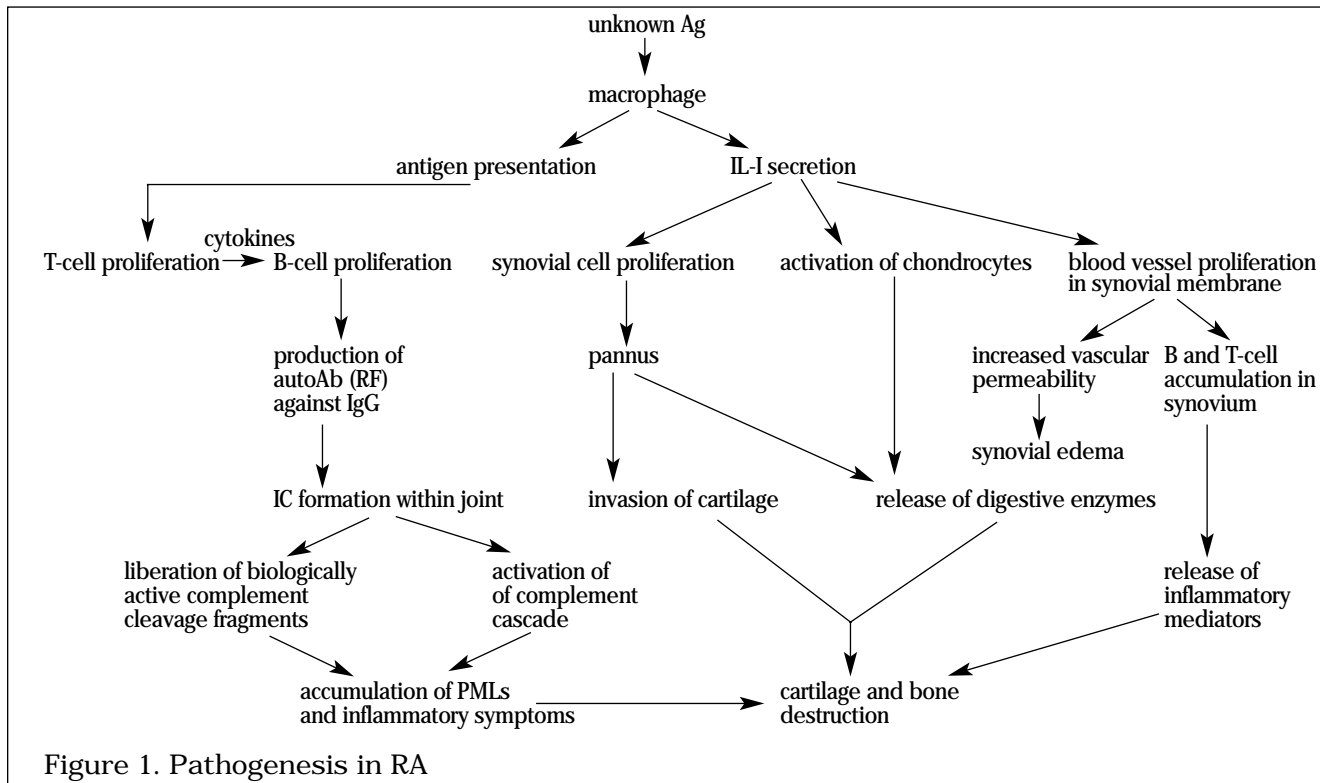


Figure 1. Pathogenesis in RA

### Diagnostic Criteria (*American Rheumatism Association, 1987*)

(4 or more of the following for 6 weeks)

1. morning stiffness (> 1 hour)
2. arthritis of three or more joint areas (commonly involved joints include PIP, MCP, wrist, elbow, knee, ankle, MTP)
3. arthritis of hand joints: MCP, PIP, wrists
4. symmetric arthritis
5. rheumatoid nodules
6. serum rheumatoid factor- found in 80% of RA patients
7. x-ray changes: erosions, most likely to see earliest changes at the ulnar styloid, at the 1st and 2nd MCP joints and at the 1st and 2nd PIP joints

Table 5. Clinical Manifestations

Stage	Symptoms	Signs	Radiographic Changes
1	usually none	—	—
2	malaise, mild joint stiffness and swelling	swelling of small joints of hands or wrists or pain in hands, wrists, knees and feet	—
3	joint pain and swelling AM stiffness, malaise and weakness	warm, swollen joints, excess synovial fluid, soft tissue proliferation within joints, pain and limitation of motion, rheumatoid nodules	soft tissue swelling
4	same as Stage 3	Stage 3 but more pronounced swelling	MRI - proliferative pannus x-ray - periarticular osteopenia
5	Stage 3 and loss of function and early deformity (eg. ulnar deviation at MCP joint)	Stage 3 and joint instability, flexion contractures, decreased ROM, extra-articular complications	early erosions, joint space narrowing

clinical course highly variable --> sporadic, insidious, aggressive or severe polyarticular synovitis with extra-articular organ involvement

### Complications

- joint deformities such as swan neck, boutonniere, ulnar deviation, hammer toes, flexion contractures
- atlanto-axial subluxation
  - long tract signs
  - limited shoulder mobility, dislocation, spontaneous tears of the rotator cuff leading to chronic spasm
- tendon sheath involvement
  - tenosynovitis --> may cause rupture of tendons
  - tingling of thumb and first finger
- compression of carpal tunnel and thenar atrophy
- ruptured Baker's cyst (outpouching of synovium behind the knee); presentation similar to DVT
- anemia of chronic disease
- high ESR, hypergammaglobulinemia

### Extra-Articular Features (EAF)

- can be classified in terms of the underlying process which is either a vasculitis or a lymphocytic infiltrate

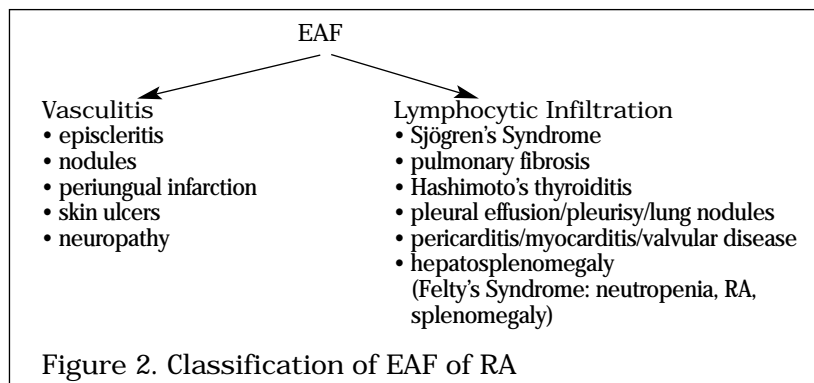


Figure 2. Classification of EAF of RA

### Management

- goal: to control inflammation, relieve pain and stiffness, maintain function and prevent joint damage
- A. Education, occupational therapy, dietary therapy (e.g. selenium)
- B. Medical Therapy
- NSAIDs --> DMARDs +/- steroids
  - Steroids
    - Intraarticular: frequent
    - Systemic: elderly, severe refractory disease, function necessary for employment
1. Non-Steroidal Anti-Inflammatory Drugs (NSAIDs)
- do not alter natural history of RA
  - need high doses to get anti-inflammatory effects (3-4 g/day)
  - no significant difference in efficacy among NSAIDs
  - often used with prostaglandin E analog, misoprostol
  - mechanism of action
    - decrease prostaglandin synthesis by inhibiting cyclooxygenase - traditional NSAIDs inhibit both COX-1 and 2 vs. COX-2 specific inhibitors
    - inhibit leukocyte and monocyte function
  - COX-1 inhibitors - renal, GI, platelet side-effects
  - COX-2 inhibitors (e.g. Celebrex) have better GI and hematologic safety profile, not more effective pain relief
2. Disease Modifying Antirheumatic Drugs (DMARDs)
- induce disease remission, unlike NSAIDs
  - delayed onset of action (8-12 weeks)
  - commonly used DMARDs: antimalarials (e.g. hydroxychloroquine), gold, methotrexate, sulfasalazine
  - rarely used DMARDs: azathioprine (Imuran), penicillamine, cyclophosphamide
  - mild disease: hydroxychloroquine, sulfasalazine

- moderate to severe disease:
  - single regimen with methotrexate, gold or imuran
  - combination therapy
    - methotrexate, sulfasalazine and chloroquine
    - methotrexate and cyclosporine
- new inhibitors: TNF inhibitors +/- methotrexate, leflunomide
- 3. Corticosteroids
  - most potent anti-inflammatory agents available and are useful in the therapy of an acute flare, but in clinically acceptable doses do not influence the natural course of disease in RA
  - local use
    - intra-articular injections for control of inflammation in specific joints
    - eye drops for scleritis or episcleritis
  - systemic use
    - high doses for vasculitis
    - low doses while awaiting onset of second-line drugs
    - supplement action of NSAIDs in elderly
    - cardiopulmonary involvement
    - individuals who are active
- 4. Experimental Therapy
  - biological agents such as anti-IL2, anti-CD4+, anti RF idiotype, and TNF inhibitors (approved in USA)
- C. Surgical Therapy
  1. Synovectomy
    - local destruction or removal of inflamed synovium from individual joints (surgical or radioactive)
    - produces long term effect
  2. Joint Replacement
    - hip, shoulder, knee
  3. Joint Fusion
    - wrist, thumb, C-spine

Table 6. Drugs Used in the Treatment of Rheumatic Diseases

Drug	Side Effects	Cautions/Contraindications
Acetaminophen	liver/kidney damage	alcohol, abuse, liver/kidney disease
NSAIDs	GI pain, ulcers, bleeding tinnitus, dizziness, drowsiness rash renal failure, nephrotic syndrome hepatitis	kidney/liver disease allergies to ASA/NSAIDs use of anticoagulants peptic ulcer disease
Corticosteroids	osteoporosis, avascular necrosis hypertension cataracts, glaucoma peptic ulcer psychosis susceptibility to infection hypokalemia, hyperglycemia, hyperlipidemia	active infections osteoporosis hypertension gastric ulcer diabetes
Gold	rash, mouth soreness/ulcers proteinuria, marrow suppression	IBD kidney/liver disease
Hydroxychloroquine	GI symptoms, retinopathy, neuromyopathy, skin rash	retinal disease, G6PD deficiency
Penicillamine	rash, loss of taste/appetite, GI symptoms	Penicillin allergy hematologic/kidney disease
Sulfasalazine	GI symptoms, headache, low blood count, rash	allergy to sulfa drugs/ASA kidney disease
Azathioprine	pancytopenia, biliary stasis, rash, hair loss, vomiting, diarrhea	kidney/liver disease
Methotrexate	urticaria, N/V&D, tubular necrosis, leukopenia, thrombocytopenia, cirrhosis, pneumonitis, oral ulcers	bone marrow suppression liver disease immunodeficiency, pregnancy
Cyclophosphamide	cardiotoxicity, N/V&D, hemorrhagic cystitis, nephrotoxicity, bone marrow suppression	kidney/liver disease pregnancy
Cyclosporine	bleeding, hypertension, decreased renal function, hair growth, tremors/shaking	kidney/liver disease infection, hypertension

### SYSTEMIC LUPUS ERYTHEMATOSUS (SLE)

- ❑ disorder characterized by inflammation in several organ systems and the production of autoAb that participate in immunologically mediated tissue injury

#### Epidemiology

- ❑ incidence F:M = 8:1
- ❑ age of onset in reproductive years, 13-40
- ❑ more common in Blacks and Asians
- ❑ bimodal mortality pattern
  - early (within 2 years)
    - active SLE
    - active nephritis
    - infection secondary to steroid use
  - late (> 10 years)
    - inactive SLE
    - inactive nephritis
    - atherosclerosis possibly secondary to long term steroid use

#### Proposed Etiology

- ❑ altered immunity
  - too many autoAb causing damage by cytotoxic effects or Ag-Ab complexes
  - altered regulating mechanism e.g. decreased T-suppressors or defective function
- ❑ heredity
  - common HLA B8, DR3 (approximately 10% have positive family history)
- ❑ role of estrogen
  - prepubertal and postmenopausal women have similar incidence to men
  - men who develop lupus have a higher concentration of estrogenic metabolites
- ❑ infection
  - virus (nonspecific stimulant of immune response)
- ❑ drugs
  - anticonvulsants (dilantin, phenobarbital)
  - antihypertensives (hydralazine)
  - antiarrhythmics (procainamide)
  - oral contraceptive pills
  - anti-histone antibodies are commonly seen in drug induced lupus

#### Diagnostic Criteria

- ❑ person is diagnosed with SLE if any 4 or more of the 11 criteria are present serially or simultaneously
- ❑ "4,7,11" rule
  - 4 out of 11 criteria for diagnosis
  - 4 laboratory criteria
  - 7 clinical criteria
- ❑ Clinical criteria
  1. malar rash: classic "butterfly rash"; no scarring involved since basement membrane intact (see Colour Atlas L1)
  2. discoid rash: may cause scarring (see Colour Atlas L3)
  3. photosensitivity
  4. oral/nasal ulcers: usually painless
  5. arthritis: non-erosive; involving 2 or more peripheral joints
  6. serositis
    - pleuritis, pericarditis, peritonitis
  7. neurologic disorder
    - seizures, psychosis
    - headache, neuropathy
    - cytoid body = cotton wool exudates on fundoscopy = CNS involvement of lupus with infarction of nerve cell layer of the retina
- ❑ Laboratory criteria
  8. renal disorder (see Nephrology Notes)
    - proteinuria, cellular casts (RBC, Hb, granular, tubular or mixed)
    - > 0.5 g/day or 3+
  9. hematologic disorder
    - hemolytic anemia, leukopenia, lymphopenia, thrombocytopenia

- 10. immunologic disorder
  - positive LE cell preparation, anti-dsDNA Ab, anti-Sm Ab, false positive VDRL
- 11. antinuclear antibody (ANA) - most sensitive of all tests
  - ❑ other associated features: skin manifestations (urticaria, livedo reticularis, bullae, panniculitis, alopecia) vasculitic lesions (periorbital telangiectasia, Raynaud's) eye manifestations (conjunctivitis, episcleritis, keratoconjunctivitis) neuropsychiatric (personality disorders, depression, psychoses)
  - ❑ Neonatal lupus erythematosus
    - anti-Ro positive mothers with SLE
    - fetal thrombocytopenia, rash and congenital heart block
    - most neonates require pacemaker

### Clinical Pearl

- ❑ Drug-induced SLE often presents atypically with systemic features and serositis. Is usually associated with anti-histone antibodies

- ❑ lab investigations: serologic hallmark is high titre ANA (homogeneous/rim pattern)
- ❑ ANA is high sensitivity and therefore a screening test
  - anti-dsDNA Ab and anti-Sm Ab are specific for SLE
- ❑ anti-dsDNA, C3, C4 may be useful in following disease activity if serology clinically concordant

### Management Principles

- ❑ treat early using the mildest form of treatment possible, then slowly withdraw therapy
- ❑ if higher doses of steroids necessary for long-term control of disease use steroid sparing agents as well, then taper off steroids

### Treatment

- ❑ symptomatic treatment tailored to organ system involved and severity of disease
- ❑ patient education - sunblock, avoid UV light and estrogens
- ❑ NSAIDs - arthritis, pleurisy, pericarditis
- ❑ antimalarials - dermatologic and MSK manifestations, constitutional symptoms (fever, weight loss, etc...)
- ❑ topical steroids for rash
- ❑ systemic corticosteroids - prevent end organ damage secondary to inflammation (decreasing doses + slow taper)
- ❑ cytotoxic agents (steroid sparing): azathioprine, cyclophosphamide, methotrexate

### ANTIPHOSPHOLIPID ANTIBODY SYNDROME (APS)

- ❑ multisystem vasculopathy manifested by recurrent thromboembolic events, spontaneous abortions and thrombocytopenia
- ❑ circulating autoantibodies (antiphospholipid antibody and lupus anticoagulant) interfere with coagulation cascade
- ❑ primary vs. secondary
  - secondary APS develops in SLE, other connective tissue diseases, malignancy, drugs (hydralazine, procainamide, phenytoin, interferon, quinidine), infections (HIV, hepatitis C, TB, infectious mononucleosis)
- ❑ catastrophic APS
  - fatal condition with sepsis, respiratory distress syndrome, malignant hypertension, multiorgan infarction and transfusion-dependent thrombotic thrombocytopenic purpura

### Clinical Features

- ❑ primary manifestation is venous or arterial occlusion
  - venous occlusion - DVT, PE, renal and retinal vein thrombosis
  - arterial occlusion - stroke, TIA, multiinfarct dementia, chorea, myocardial infarction, valvular incompetence, limb ischemia
- ❑ recurrent fetal wastage
- ❑ hematologic abnormalities
  - thrombocytopenia, hemolytic anemia, neutropenia
- ❑ skin
  - livedo reticularis (classical lesion), purpura, leg ulcers and gangrene
- ❑ serology
  - lupus anticoagulant or anticardiolipin antibody positive on 2 occasions, at least 8 weeks apart

### Treatment

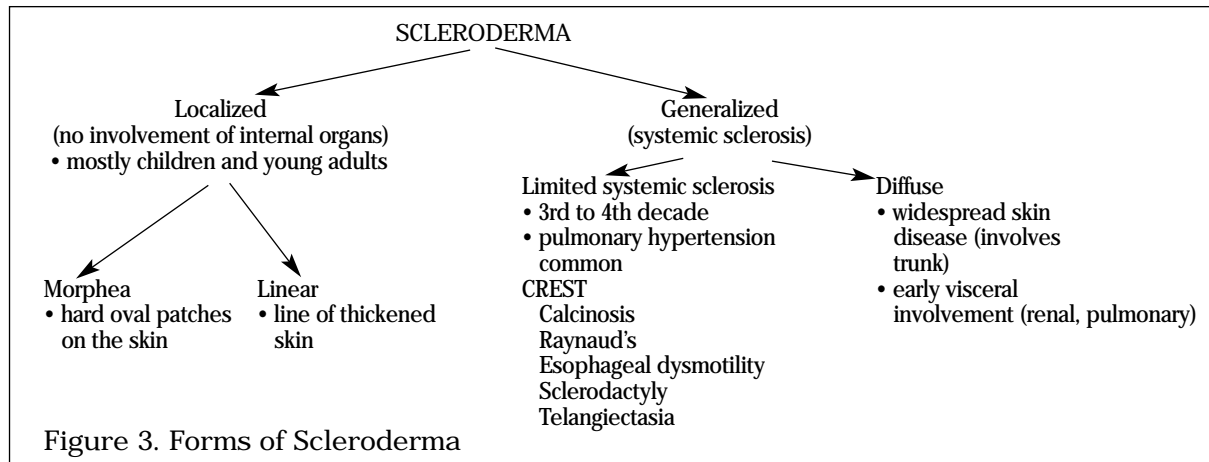
- ❑ thrombosis
  - lifelong anticoagulation with warfarin
  - target INR 2.5-3.5
- ❑ recurrent fetal loss: aspirin, heparin, +/- steroids
- ❑ catastrophic APS: high-dose steroids, anticoagulation, cyclophosphamide, plasmapheresis

### SCLERODERMA/PROGRESSIVE SYSTEMIC SCLEROSIS (PSS)

- ❑ generalized disorder of connective tissue characterized by fibrosis and degenerative changes in blood vessels, visceral organs and skin
- ❑ no inflammation
- ❑ clinical hallmarks of PSS are tight skin and Raynaud's phenomenon
- ❑ diagnosis made on clinical grounds

### Etiology

- ❑ F:M ratio 3-4:1
- ❑ incidence peaks in fifth and sixth decade
- ❑ associated with HLA DR1, DR3, DR5
- ❑ associated environmental factors
  - PSS: silica exposure, epoxy resins, aromatic hydrocarbons
  - PSS-like: polyvinyl chloride, toxic oil syndrome, contaminated L-tryptophan (eosinophilia myalgia syndrome)



### Pathogenesis

- ❑ vasculopathy (not vasculitis)
  - decreased vascular luminal size
  - intimal proliferation and medial mucinous degeneration  
--> progressive obliteration of vessel lumen --> secondary fibrosis of tissues
  - resembles malignant hypertension
  - no inflammation: atrophy and fibrosis

### Clinical Features

- ❑ skin
  - bilateral symmetrical swelling of fingers, hands and feet leading to skin tightening (see Colour Atlas L8)
  - initial phase characterized by painless pitting edema, which on resolution leaves thick, tight skin
  - characteristic face: mask-like facies, beak nose, radial perioral furrows
  - other skin changes
    - atrophy, ulcerations, hypo- and hyperpigmentation, mottled telangiectasias, calcinosis, periungual erythema
- ❑ Raynaud's phenomenon
  - clinically presents as episodes (minutes to hours) of blanching or cyanosis of digits followed by erythema, tingling and pain
  - due to vasospasm and structural disease of blood vessels following cold exposure or emotional stress
  - if severe, can result in infarction of tissue at fingertips --> digital pitting scars, frank gangrene or autoamputation of the fingers or toes



- ❑ GI tract
  - becomes a rigid tube leading to decreased motility
  - distal esophageal hypomotility --> dysphagia in substernal region
  - loss of lower esophageal sphincter function --> gastric reflux, ulcerations and strictures
  - small bowel hypomotility --> bacterial overgrowth, diarrhea, bloating, cramping, malabsorption, weight loss
  - large bowel hypomotility --> infrequent cause of constipation
    - pathognomonic radiographic finding on barium contrast studies are large bowel diverticula
- ❑ kidneys
  - "scleroderma renal crisis" may lead to malignant arterial hypertension, oliguria and microangiopathic hemolytic anemia
- ❑ lungs
  - interstitial fibrosis, pulmonary HTN, pleurisy and pleural effusions
- ❑ heart
  - left ventricular dysfunction, pericarditis, arrhythmias, pericardial effusion
- ❑ musculoskeletal
  - polyarthralgias and sometimes frank polyarthritis affecting both small and large joints
  - bones resorbed with subcutaneous calcifications (calcinosis)
  - "resorption of distal tufts" (radiological finding)
  - proximal weakness secondary to disuse atrophy/low grade inflammatory myopathy

### Diagnosis

- ❑ diagnostic criteria: 1 major or 2 or more minor of the following:
  - major criterion: proximal scleroderma
  - minor criterion: sclerodactyly, digital pitting scars or loss of substance from the finger pad, bibasilar pulmonary fibrosis
- ❑ serology: anti-topoisomerase 70 specific but not sensitive for PSS

### Treatment

- ❑ education about precautionary measures (e.g. avoid cold)
- ❑ penicillamine for scleroderma of little value; expectant treatment with methotrexate/cyclosporin
- ❑ symptomatic treatment
  - GERD: proton pump inhibitors are first line, then H<sub>2</sub> receptor antagonists, cisapride
  - small bowel bacterial overgrowth: broad-spectrum antibiotics (tetracycline, metronidazole)
  - Raynaud's: calcium channel blockers, peripheral vasodilators, local nitroglycerin cream, systemic PGE<sub>2</sub> inhibitors
  - renal disease, HTN: ACE inhibitors
  - myositis, pericarditis: steroids

### POLYMYOSITIS (PMY)/ DERMATOMYOSITIS (DMY)

- ❑ idiopathic inflammatory myopathies
- ❑ PMY is CD8 cell-mediated muscle necrosis; DMY is CD4 immune complex-mediated perifascicular vasculitis
- ❑ proximal limb and neck weakness, sometimes associated with muscle pain (early symptom is patient has difficulty lifting head off pillow)
- ❑ DMY is PMY with a characteristic rash (heliotrope, Gottron's)
- ❑ can occur with malignancy (adult form only)
  - 2.4-6.5 fold increased risk of underlying malignancy usually in internal organ (ovarian, stomach, prostate, nonmelanoma skin cancer)
  - increased risk of malignancy in females, age > 50, DMY > PMY, normal CK, refractory disease
- ❑ autoantibodies: ANA, anti Jo-1, anti-Mi-2 and other myositis-specific antibodies

### Clinical Features

- ❑ progressive symmetrical proximal muscle weakness (shoulder and hip) that develops over weeks to months
- ❑ Gottron's papules and Gottron's sign are pathognomonic of dermatomyositis (occurs in 70% of patients) (see Colour Atlas L4)



- Gottron's papules
  - violaceous, flat-topped papules overlying the dorsal surface of the interphalangeal joints
- Gottron's sign
  - erythematous smooth or scaly patches over the dorsal interphalangeal or metacarpophalangeal joints, elbows, knees, or medial malleoli
- heliotrope (purple) rash over the eyelids and usually with edema (see Colour Atlas L2)
- cardiac involvement
  - dysrhythmias, congestive heart failure, conduction defect, ventricular hypertrophy, pericarditis
- GI involvement
  - oropharyngeal and lower esophageal dysphagia, reflux
- pulmonary involvement
  - weakness of respiratory muscles, intrinsic lung pathology, aspiration

### Classification

- PMY/DMY
- Juvenile DMY (usually with vasculitis)
- PMY/DMY associated with malignancy
- PMY/DMY associated with connective tissue disease
- Amyopathic DMY
- Inclusion body myositis

### Diagnosis

- Diagnostic criteria
  - Definite PMY/DMY: fulfill 4 criteria
  - Probable PMY/DMY: fulfill 3 criteria
  - Possible DMY: fulfill 2 criteria
- 1. progressive symmetric proximal muscle weakness
- 2. muscle enzyme levels: increased CK, aldolase, LDH, transaminases
- 3. EMG: short polyphasic motor units, high frequency repetitive discharge, insertional irritability
- 4. muscle biopsy: segmental fibre necrosis, basophilic regeneration, perivascular inflammation and atrophy
- 5. cutaneous eruption typical of dermatomyositis (required for diagnosis of DMY)

### Treatment

- physical therapy
- high dose corticosteroid (1-2 mg/kg/day) and slow taper
- immunosuppressive agents
  - azathioprine, methotrexate, cyclophosphamide, cyclosporine
- intravenous immunoglobulin (DMY)
- plasmapheresis
- malignancy surveillance
  - detailed history and physical (breast, pelvic and rectal exam)
  - CXR, abdominal ultrasound, stool occult blood, pap smear, mammogram

### MIXED CONNECTIVE TISSUE DISEASE (MCTD)/OVERLAP SYNDROME

- combination of RA, SLE, scleroderma, and polymyositis and high titres of anti-ribonucleoprotein Ab (anti-RNP)
- anti-RNP "speckled ANA fluorescence" but absence of Ab to dsDNA, Sm and histones
- patient may have rash, RA, mouth and face of PSS
- "a disease in evolution" or an undifferentiated connective tissue disease
  - 50-60% will evolve into SLE
  - 40% will evolve into scleroderma
  - only 10% will remain as MCTD for the rest of their lives

### SJÖGREN'S SYNDROME

- chronic, inflammatory disorder, likely autoimmune, characterized by CD4/CD8 cell mediated infiltration and destruction of salivary and lacrimal glands
- results in "sicca complex": dry eyes, dry mouth (keratoconjunctivitis sicca, xerostomia)
- may evolve from an organ specific to systemic disorder

- ❑ systemic manifestations include arthralgias/arthritis, subclinical diffuse interstitial lung disease, renal disease, palpable purpura, systemic vasculitis, lymphoma, Waldenström's macroglobulinemia
- ❑ antibodies commonly seen in Sjogren's include anti-La, anti-Ro, RF, ANA
- ❑ occurs in connective tissue diseases and HIV

### Diagnosis

- ❑ assess tear flow (Schirmer test)
- ❑ slit lamp exam with Rose Bengal stain
- ❑ salivary flow measurements
- ❑ sialography
- ❑ salivary gland biopsy: gold standard
- ❑ autoantibodies: anti-Ro and -La

### Treatment

- ❑ good dental hygiene (dental caries increase secondary to decreased saliva volume and its antibacterial factors)
- ❑ artificial tears or surgical punctal occlusion for xerophthalmia
- ❑ adequate hydration for xerostomia
- ❑ hydroxychloroquine, corticosteroids, immunosuppressive agents for severe systemic involvement

# SEROPOSITIVE RHEUMATIC DISEASES: VASCULITIDES

### Vasculitis (see Colour Atlas L7)

- ❑ inflammation and necrosis of blood vessels with resulting tissue ischemia/infarction
- ❑ keys to diagnosis
  - clinical suspicion (presentation is non-specific)
  - labs non-specific: anemia, increased WBC and ESR, abnormal urinalysis
  - biopsy if tissue accessible
  - angiography if tissue inaccessible
- ❑ treatment generally entails corticosteroids and/or immunosuppressives

### Etiology

- ❑ immune-mediated
  - Type I: Churg-Strauss
  - Type II: Small vessel vasculitis, microscopic polyangiitis, Wegener's
  - Type III: PAN
  - Type IV: giant cell arteritis

Table 8. Classification of Vasculitis

Small vessel
• Cutaneous (hypersensitivity vasculitis)
• Wegener's granulomatosis
• Churg-Strauss vasculitis
• Microscopic polyangiitis
• HSP
• Essential cryoglobulinemic vasculitis
• Cutaneous leukocytoclastic vasculitis
Medium-sized vessel
• PAN
• Kawasaki's
Large vessel
• Giant Cell Arteritis (Temporal Arteritis)
• Takayasu's

### CUTANEOUS (HYPERSENSITIVITY) VASCULITIS

- ❑ most common type of vasculitis
- ❑ immune reaction to drugs, infection, diseases such as SLE, RA, malignancies

### Etiology

- ❑ usually cutaneous vasculitis following drug exposure, a viral or bacterial infection

### Pathology

- small vessels involved (post capillary vessels most frequently)
- leukocytoclastic vasculitis = debris from neutrophils around vessels
- sometimes due to cryoglobulins which precipitate in cold temperatures thus affecting vessels on the body surface

### Clinical Features

- skin
  - palpable purpura +/- vesicle formation and ulceration, urticaria
- kidney
  - hematuria, proteinuria and renal insufficiency

### Diagnosis

- vascular involvement established by biopsy

### Treatment

- stop possible offending drug
- usually self limited
- corticosteroid +/- immunosuppressive agents

## WEGENER'S GRANULOMATOSIS

- granulomatous inflammation of small and medium sized arteries and veins of respiratory tract and kidneys
- most common in middle age
- pathophysiology: may be secondary to URTI
- transformation from inflammatory prodrome (serous otitis media and sinusitis) to full blown vasculitic syndrome

### Clinical Features

- systemic
  - malaise, fever, weakness, weight loss
- respiratory
  - URTI: sinusitis or rhinitis, nasoseptal perforation, saddle nose deformity, otitis media, and extension into the orbit with proptosis
  - LRTI: cough, hemoptysis, tracheobronchial erosion, pneumonitis, cavity formation
- kidney
  - segmental necrotizing glomerulonephritis (vasculitis rarely seen)
- other
  - joint, skin, eye complaints

### Diagnosis

- blood work
  - specific: ANCA (c-ANCA > p-ANCA)
  - general: anemia, leukocytosis, elevated ESR
- urinalysis: protein, RBC casts
- radiology: chest x-ray may show nodules, cavitations (see Colour Atlas K5)
- biopsy of involved tissue: lungs show granulomas, kidneys show focal segmental glomerulonephritis

### Treatment

- cyclophosphamide 2 mg/kg/day PO (12-18 months) and concurrent corticosteroid therapy with fast steroid taper
- alternative treatment immunosuppressive agents (e.g. MTX)

## POLYARTERITIS NODOSA (PAN)

### Epidemiology

- any age (average 40's-50's)

### Etiology

- unknown in most cases

### Pathology

- focal panmural necrotizing inflammatory lesions in small and medium-sized arteries
- thrombosis, aneurysm or dilatation at lesion site may occur
- healed lesions show proliferation of fibrous tissue and endothelial cells that may lead to luminal occlusion
- may involve one or many organ systems: most commonly affects joints, kidneys, peripheral nerves, GI, skin

### Clinical Features

- joints
  - arthralgia and arthritis usually early in course
- kidneys
  - aneurysms leading to renal insufficiency
  - hypertension (25% of patients)
- peripheral nervous system
  - peripheral neuropathy with sudden pain, paresthesia, motor deficit, and mononeuritis multiplex
- GI
  - abdominal pain, hematemesis, melena, ischemic bowel
- skin
  - palpable purpura, ulceration, livedo reticularis and digital tip infarct
- heart
  - myocardial infarction and congestive heart failure
- associated conditions
  - Churg-Strauss: pulmonary involvement, with allergic manifestations such as asthma, eosinophilia

### Diagnosis

- vascular involvement established by biopsy or angiography

### Treatment

- prednisone 1 mg/kg/day PO; cyclophosphamide 2 mg/kg/day PO

## MICROSCOPIC POLYANGIITIS

- vasculitis affecting small vessels
- pauci-immune
- affects kidneys (focal segmental glomerulonephritis), lungs (capillaritis and alveolar hemorrhage), skin
- strongly associated with ANCA (p-ANCA > c-ANCA)

## GIANT CELL ARTERITIS (TEMPORAL ARTERITIS)

- EMERGENCY SITUATION - untreated can lead to blindness (20-25%)
- inflammation of medium and large sized arteries, predominantly those originating from the arch of the aorta

### Clinical Features

- over 50 years of age, more common in women
- temporal headaches and scalp tenderness due to inflammation of the involved portion of the temporal or occipital arteries
- sudden, painless loss of vision, diplopia and/or permanent visual loss due to narrowing of the ophthalmic or posterior ciliary arteries
- tongue and jaw claudication (pain in muscles of mastication on chewing)
- polymyalgia rheumatica (proximal myalgia, constitutional symptoms, elevated ESR) occurs in 30% of patients
- aortic arch syndrome; involvement of subclavian, brachial, branches of aorta result in pulseless disease, aortic aneurysm +/- rupture

### Diagnosis

- clinical suspicion, increased ESR, temporal artery biopsy, angiography

### Treatment

- high dose prednisone 1 mg/kg in divided doses until symptoms resolve
- azathioprine or methotrexate if refractory
- highly effective in the treatment of giant cell arteritis and in the prevention of blindness and other vascular complications

## OTHER VASCULITIDES

- ❑ Takayasu's arteritis
  - chronic inflammation of larger arteries, most often affecting the aorta and its branches
  - usually young adults of Asian descent
  - female > male
- ❑ Buerger's disease
  - also known as thromboangiitis obliterans
  - inflammation is secondary to pathological clotting
  - affects small and medium-sized arteries and veins of the distal extremities
  - the most important etiological factor is heavy cigarette smoking, most common in Asian males
  - may lead to distal claudication, gangrene
  - therapy requires smoking cessation

## SERONEGATIVE RHEUMATIC DISEASES

Table 8. Features of Seronegative Disease

	Sacro-iliac Joint	Spondylitis	Peripheral Arthritis	Iritis	Aortitis
AS	++++	+++	++	+++	+
IBD	++	++	++	+	
Reactive	+	+	+++	+	
Reiter's	++	++	++++	++	+
Psoriatic	+	+	++++		

## ANKYLOSING SPONDYLITIS (AS)

- ❑ prototype of the spondyloarthropathies
- ❑ characterized by
  - enthesopathy, sacroiliitis, spondylitis
  - inflammatory ocular diseases
  - asymmetric oligoarthritis, mostly large
  - genitourinary disease: prostatitis
  - HLA B27 association

### Epidemiology

- ❑ incidence 0.2% of general population
- ❑ male predominance, females milder disease
- ❑ age of onset is usually late teens or early twenties
- ❑ 90% of patients with AS have HLA B27

### Pathology

- ❑ enthesitis
  - inflammation of ligament where it attaches to bone

### Clinical Features

- ❑ joints
  - axial arthritis, i.e. mid and low back stiffness and pain
  - spinal restriction in 3 planes

### Clinical Pearl

- ❑ Remember to check for changes in lateral chest wall expansion (normal > 5cm at T4)

- persistent buttock pain especially at rest
- sacroiliitis, peripheral arthritis of hips and shoulders
- asymmetrical large joint involvement; most often in lower limb
- enthesitis: Achilles tendinitis, plantar fasciitis and iliac crest tenderness
- complications: flexion contractures of hip, spinal fractures, apophyseal fusion
- ❑ extra-articular manifestations
  - acute anterior uveitis (25-30% patients)
  - heart: aortitis, aortic regurgitation, heart failure (rare)

- kidney: amyloidosis and IgA nephropathy
- pulmonary: apical fibrosis (rare)
- cauda equina syndrome

#### Diagnosis

- ❑ physical exam: increased occiput-to-wall distance, decreased chest expansion, loss of normal lumbar lordosis and increased thoracic kyphosis, painful sacroiliac joint, modified Schöber
- ❑ x-ray of SI joint: radiographic "pseudowidening" of joint due to erosion with joint sclerosis → bony fusion
- ❑ x-ray of spine: radiographic appearance of "squaring of edges" from erosion and sclerosis on corners of vertebral bodies leading to bridging syndesmophytes, producing a bamboo spine radiographically
- ❑ HLA B27: 90% sensitive in Caucasians

#### Treatment

- ❑ heat
- ❑ prevention of deformity and disability
  - exercise (e.g. swimming)
  - postural and deep breathing exercises
  - prevent fusion in poor posture
- ❑ medication
  - NSAIDs: do not alter natural history
  - DMARDs for peripheral arthritis (sulfasalazine, methotrexate)
- ❑ manage extra-articular manifestations

#### Prognosis

- ❑ spontaneous remissions and relapses are common and can occur at any age
- ❑ despite spinal deformity function may be excellent
- ❑ good if female and onset after age 40
- ❑ early onset with hip disease may lead to severe disability, may require arthroplasty

### REACTIVE ARTHRITIS

- ❑ a generic term for arthritis following an infection e.g. rheumatic fever, Reiter's
- ❑ Reiter's syndrome: classic triad (urethritis, conjunctivitis, arthritis) with mucocutaneous lesions
- ❑ the arthritis is not due to an organism within the joint space but is a reaction to the infection (cultures of synovial fluid are sterile)
- ❑ manage ophthalmologic and other manifestations

#### Epidemiology

- ❑ 90% of patients are male, aged 20-40, and positive for HLA B27

#### Etiology

- ❑ onset following an infectious episode either involving the GI or GU tract
  - GI: *Shigella*, *Salmonella*, *Sampylobacter*, *Yersinia* species
  - GU: *Chlamydia*, *Mycoplasma* species
- ❑ acute pattern of clinical course
  - one week post-infection
  - lasts weeks to years with 1/3 chronic
  - often recurs
  - spinal involvement persists

#### Clinical Features

- ❑ peripheral arthritis, asymmetric pattern
- ❑ iritis, plantar fasciitis, Achilles tendonitis, oral ulcers, spondylitis (thick and skipped syndesmophytes), diarrhea
- ❑ keratoderma blenorrhagica (hyperkeratotic skin lesions on palms and soles) and balanitis circinata (small, shallow, painless ulcers of glans penis and urethral meatus) are diagnostic
- ❑ sausage digits are characteristic of Reiter's and psoriatic arthritis

#### Diagnosis

- ❑ clinical
- ❑ lab finding: normocytic, normochromic anemia, leukocytosis, increased ESR

#### Treatment

- ❑ appropriate antibiotics if there is documented infection
- ❑ NSAIDs, physical therapy

- ❑ local therapy
  - joint protection
  - intra-articular steroid injection
  - topical steroid for ocular involvement
- ❑ systemic therapy
  - DMARDs, corticosteroids, sulfasalazine, methotrexate
- ❑ manage ophthalmic and other manifestations

**PSORIATIC ARTHRITIS**

- ❑ arthropathy in 10% of patients with psoriasis

**Etiology**

- ❑ unclear but possible important environmental factors include psoriatic plaque flora, particularly Group A Streptococci, and trauma

**Clinical Features**

- ❑ skin and nail changes are typical findings
  - well-demarcated erythematous plaques with silvery scale
  - nail involvement includes pitting, transverse or longitudinal ridging, discoloration, subungual hyperkeratosis, and onycholysis
- ❑ joints
  - asymmetric oligo-articular involvement with symmetric peripheral arthritis (RA-like)
  - dactylitis creating sausage-like appearance
  - 5% progress to arthritis mutilans
  - sacroiliitis and spondylitis
  - floating syndesmophytes
  - pencil and cup appearance at IP joints on x-ray
- ❑ eye
  - conjunctivitis, iritis
- ❑ heart and lung
  - aortic stenosis, apical lung fibrosis
- ❑ peripheral nervous system
  - cauda equina claudication

**Treatment**

- ❑ treat skin disease (e.g. steroid cream, salicylic acid, tar)
- ❑ NSAIDs
- ❑ intra-articular steroids if NSAIDs fail to reduce synovitis and pain
- ❑ severe disease with erosive arthritis
  - disease-modifying agents e.g. sulfasalazine and hydroxychloroquine
  - immunosuppressive agents e.g. methotrexate and azathioprine

**INFLAMMATORY BOWEL DISEASE (IBD) (see Gastroenterology Notes)**

- ❑ particular manifestations of ulcerative colitis and Crohn's disease include peripheral arthritis (large joint, asymmetrical), spondylitis and hypertrophic osteoarthropathy
- ❑ arthralgia, myalgia, osteoporosis and aseptic necrosis of bone secondary to glucocorticoid treatment of the bowel inflammation

	Spondylitis	Peripheral Arthritis
HLA-B27 association	yes	no
gender	male > female	male = female
onset before IBD	yes	no
parallels IBD course	no	yes
type of IBD	UC = Crohn's	Crohn's

**GOUT**

- ❑ derangement in purine metabolism resulting in hyperuricemia, monosodium urate crystal deposits in tissues (tophi), microtophi (synovium) and recurrent episodes of acute arthritis

**Epidemiology**

- ❑ most common in males > 45 years old
- ❑ extremely unlikely for premenopausal female to get gout

**Mechanism of Uric Acid Production**

- ❑ sources of uric acid: diet and endogenous
- ❑ synthesis
  - hypoxanthine → xanthine → uric acid
  - both steps catalyzed by xanthine oxidase

**Hyperuricemia**

- ❑ due to dietary excess, overproduction of urate (< 10% of cases), or relative undersecretion of urate (> 90% of cases)
- ❑ primary or genetic
  - mostly due to idiopathic renal undersecretion (90%)
  - also idiopathic overproduction or abnormal enzyme production/function
- ❑ secondary
  - undersecretion
    - renal failure
    - drugs: diuretics, ASA, ethanol, cyclosporine, levodopa, ethambutol, vitamin B12, nicotinic acid
    - conditions: sarcoidosis, hypothyroidism, hyperparathyroidism, trisomy 21, preeclampsia/eclampsia
  - overproduction
    - increased nucleic acid turnover: hemolysis, myeloproliferative disease, lymphoproliferative disease, psoriasis, rhabdomyolysis, exercise, ethanol, obesity
- ❑ majority of people with hyperuricemia do not have gout, and normal or low uric acid levels do not rule out gout
- ❑ sudden changes in uric acid levels, temperature and pH are more important than actual levels
- ❑ common precipitants: alcohol use, dietary excess, dehydration (e.g. thiazide and loop diuretics), trauma, illness, surgery, tumour lysis syndrome
- ❑ other associated conditions: hypertension, obesity, diabetes, starvation

**Clinical Presentation**

- ❑ acute gouty arthritis (see Colour Atlas L5)
  - painful, usually involving lower extremities
  - precipitation of urate crystals in the joint space often the first metatarsophalangeal joint (podagra)
  - inflammation of big toe with spread to midtarsal or ankle (cluster attacks)
  - looks like cellulitis, but in cellulitis will be able to move joint
  - attack will subside on its own within several days-weeks and may or may not recur
- ❑ tophi
  - deposits in cartilage, tendons, bursae, soft tissues and synovial membranes
  - common sites: 1st MTP, ear helix, Achilles tendon, olecranon bursae
  - painless, but limit joint mobility
- ❑ kidney
  - gouty nephropathy
  - uric acid calculi

**Diagnosis (see Colour Atlas L6)**

- ❑ need to demonstrate crystals of monosodium urate in joint aspirate
- ❑ negative birefringence, needle-shaped crystals within the WBC of synovial fluid under polarizing lens
- ❑ differential diagnosis includes pseudogout, trauma, sepsis, OA

**Treatment**

- ❑ treatment of acute gout
  - NSAIDs: high dose, then taper as symptoms improve (polyarticular gout)
  - corticosteroids (renal disease, GI disease)



- allopurinol can worsen an acute attack
- colchicine within 1st 24 hours but effectiveness limited by low therapeutic/toxic ratio
- treatment of gout or renal disease secondary to hyperuricemia/hyperuricosuria
  - not the same as treatment of acute gout
  - avoid foods with high purine content (e.g. visceral meats, sardines, shellfish, beans, peas)
  - avoid drugs with hyperuricemic effects (e.g. pyrazinamide, ethambutol, thiazide)
  - antihyperuricemic drugs
    - drugs that decrease uric acid production (allopurinol inhibits xanthine oxidase)
    - uricosuric drugs (probenecid, sulfinpyrazone) if fail allopurinol or intolerant to allopurinol
  - note that initiating any antihyperuricemic therapy may precipitate an acute gouty attack due to a rapid change in serum urate concentration
  - prophylaxis prior to starting antihyperuricemic drugs: colchicine/NSAID

	Gout	Pseudogout
gender	males > females	males = females
age	middle-age for males post-menopausal females	older
onset of disease	acute	acute/insidious
crystal	negative birefringence, needle-shaped	positive birefringence, rhomboid-shaped
distribution	first MTP, foot	knee, hand, polyarticular
radiology	"holes in bones"	chondrocalcinosis OA (knee, wrist, 2nd and 3rd MCP)
treatment	Indocid, Colchicine	NSAIDs

## PSEUDOGOUT (CHONDROCALCINOSIS)

- acute inflammatory arthritis due to phagocytosis of IgG-coated calcium pyrophosphate dihydrate (CPPD) crystals by neutrophils and subsequent release of inflammatory mediators

### Epidemiology

- elderly
- slower onset and lasts up to 3 weeks but self-limited
- more frequently polyarticular compared to gout
- risk factors: old age, advanced OA, neuropathic joints
- other associated conditions: hyperparathyroidism, hypothyroidism, hypomagnesemia, hypophosphatasia (low ALP), diabetes, hemochromatosis

### Clinical Features

- pain
- affects knee, wrist, hand, foot and big toe
- may be triggered by dehydration, acute illness, surgery

### Diagnosis

- x-rays show chondrocalcinosis: punctate radiodensities in fibrocartilaginous structures (e.g. knee menisci) or linear radio densities in hyaline articular cartilage
- chondrocalcinosis seen in 75% of pseudogout
- must aspirate joint and do appropriate analysis to rule out septic arthritis, gout
- positive birefringence, rhomboid-shaped crystals in the synovial fluid and within neutrophils under polarizing light
- differential diagnosis includes gout, trauma, sepsis, RA

### Treatment

- aspiration of joint, rest and joint protection
- NSAIDs
  - also used for maintenance therapy
- prophylactic colchicine PO (little benefit)
- intra-articular steroids to relieve inflammation

- EMERGENCY SITUATION - permanent joint damage can occur rapidly
- an acute monoarthritis

## Etiology

- bacteria introduced to joint hematogenously (most common in adults) or 2° to osteomyelitis (most common in children) occasionally due to trauma or skin infection

## Common Organisms

- N. gonorrhoeae*: accounts for 75% of septic arthritis in young adults
- S. aureus*: affects all age - rapidly destructive
- Gram negatives: affects debilitated patients - rapidly destructive
- S. pneumoniae*: affects children
- H. influenzae*: affects infants (especially if incomplete immunization)
- Salmonella* spp.: characteristic of sickle cell

## Predisposing Factors

- extra-articular infection (e.g. GU tract, skin, lung)
- chronic illness (e.g. RA, DM, malignancy)
- prior drug use (e.g. antibiotics, immunosuppressives)
- prior joint damage (e.g. OA, RA)
- suppressed immune status (e.g. SLE, HIV)

## Clinical Features

- preceding bacteremia with skin lesions and migrating polyarthritis settling to monoarthritis often of a large joint
- joint acutely inflamed, fever
- gonococcal triad: tenosynovitis next to inflamed joint, skin changes

## Diagnosis

- high index of suspicion
- do culture and sensitivity from synovial fluid, blood, skin, rectum, endocervix or oropharynx
- growth of GC from synovial fluid is successful in < 50% of cases; therefore, Gram stain is more useful

## Treatment

- surgical drainage if
  - >72 hours of persistent infection
  - hip joint involvement
- IV antibiotics should be started empirically; third generation cephalosporin + penicillinase resistant synthetic penicillin (e.g. ceftriaxone + cloxacillin) should be given empirically before culture results come back; delay results in joint destruction
- Gram stain guides subsequent treatment
- no need to give intra-articular antibiotics, but do daily joint aspirations until culture sterile
- physiotherapy
- intra-articular steroids are contraindicated in septic arthritis

# NON-ARTICULAR RHEUMATISM

- disorders that primarily affect soft tissues or periarticular structures
- includes bursitis, tendonitis, tenosynovitis and fibromyalgia (fibrositis)

## FIBROMYALGIA

- chronic, diffuse pain with characteristic tender points and disturbed sleep

## Epidemiology

- women aged 25 to 45, some adolescents
- cardiovascularly unfit
- depressed
- patient leads a normal life prior to onset of fibromyalgia (onset often after car accident)
- shares features with chronic fatigue syndrome and myofascial pain syndrome

## Pathology

- laboratory investigations reveal no changes adequate to account for tenderness and no inflammation

## Clinical Features

- widespread aching, stiffness and reproducible tender points
  - due to referred pain
  - 11 of 18 tender points, on palpation

- poor cervical support while sleeping
- chronic hyperextension of lumbar spine
- non-restorative sleep syndrome, fatigue
- patient feels that joints are swollen but physical examination is normal
- dermatographia (redness after touching tender points)
- hyperalgesia
- difficulty falling asleep and awoken frequently
- irritable bowel syndrome
- migraines
- obesity
- ligamentous laxity
- increase urinary frequency
- depression
- paresthesias

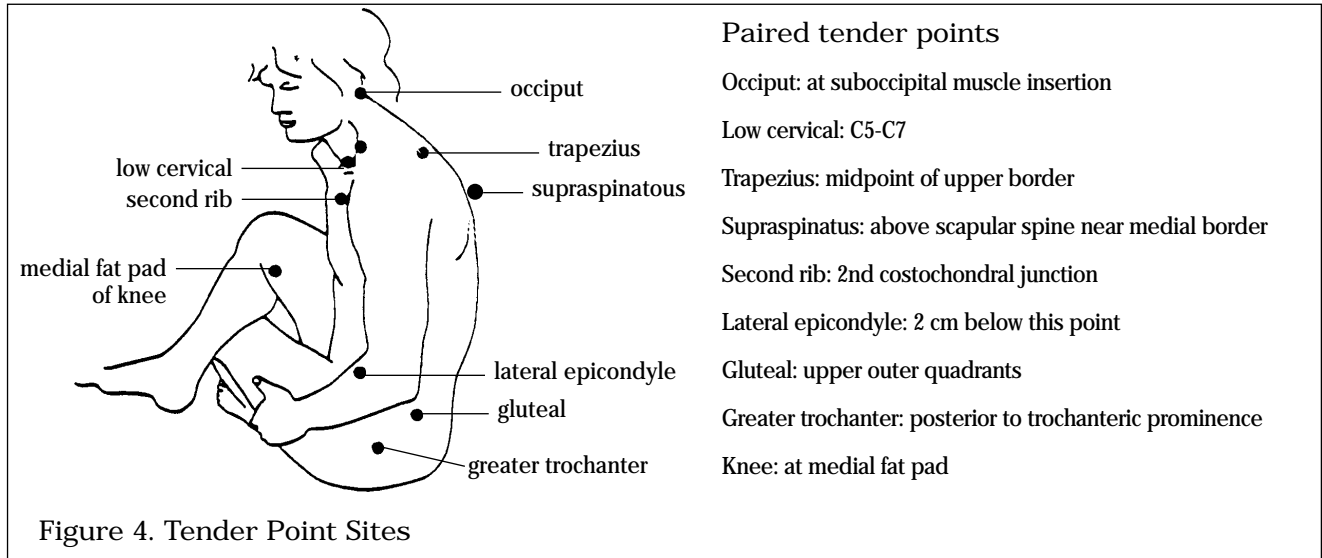


Figure 4. Tender Point Sites

### Diagnosis

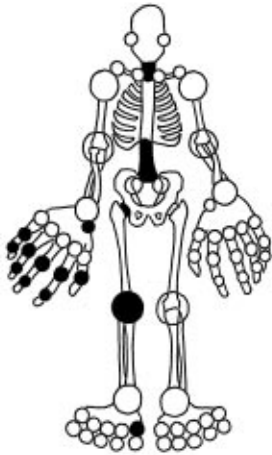
- clinical diagnosis of exclusion but often superimposed on chronic inflammatory disease (e.g. RA, SLE)
- history of tender points (11/18)
- normal lab results
- consider numerous other causes (e.g. polymyositis, polymyalgia rheumatica)

### Treatment

- education - disease is benign, non-deforming, does not progress
- develop high level of general fitness
- save back and neck: neck support while sleeping, abdominal muscle strengthening exercises
- stress reduction
- medical therapy
  - NSAIDs
  - benzodiazepines
  - tricyclic antidepressants (for sleep restoration)

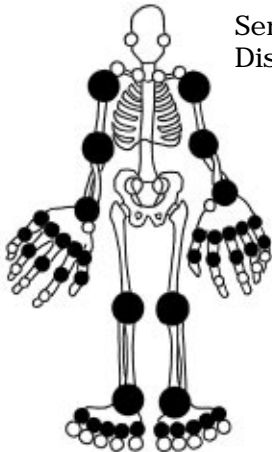
### POLYMYALGIA RHEUMATICA

- pain and stiffness in muscles of neck, shoulders, upper arms, lower back and thighs
- incidence 54 per 100 000
- F:M = 2:1
- age of onset > 50
- closely related to giant cell arteritis
- clinical presentation: slow onset and progression of aching, morning stiffness, myalgia, painful shoulder/hip girdle, synovitis; constitutional features (fever, weight loss, malaise, anorexia)
- physical exam: tender muscles with no weakness or atrophy, synovitis (knee, shoulder, hip)
- lab investigations: increased ESR, anemia, normal CK
- immediate (within 24-48 hours) and dramatic response to steroids
- treat with 2 year course of steroids 10-20 mg PO daily with slow taper



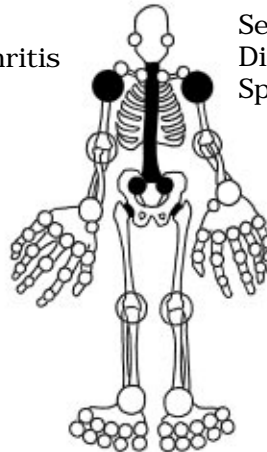
**Degenerative Arthritis:  
Osteoarthritis**

- hand (DIP, PIP, 1st CMC)
- hip
- knee
- 1st MTP
- L-spine (L4-L5, L5-S1)
- C-spine
- uncommon: ankle, shoulder, elbow, MCP, rest of wrist



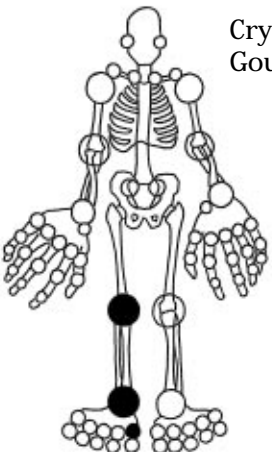
**Seropositive Rheumatic  
Diseases: Rheumatoid Arthritis**

- PIP
- MCP
- wrist, not 1st CMC
- elbow
- shoulder
- knee
- ankle
- MTP



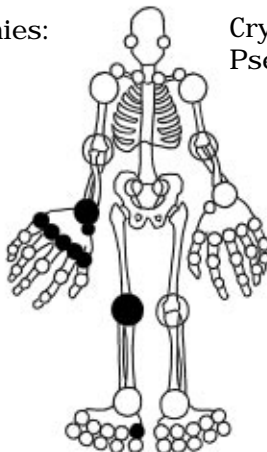
**Seronegative Rheumatic  
Diseases: Ankylosing  
Spondylitis**

- SI
- spondylitis
- hip
- shoulder



**Crystal-Induced Arthropathies:  
Gout**

- 1st MTP
- ankle
- knee



**Crystal-Induced Arthropathies:  
Pseudogout**

- knee
- polyarticular wrist
- hand (MCP)
- foot (1st MTP)

*Drawing by Lima Colati*