Journal of Musculoskeletal Research, Vol. 4, No. 2 (2000) 145–149
© World Scientific Publishing Company

CASE REPORT

GIANT OSTEOCHONDRAL LOOSE BODY OF THE KNEE JOINT

Mustafa Yel[*,‡], Mustafa Cihat Avunduk[†], Recep Memik[*] and Abdurrahman Kutlu[*]

[*]*Orthopedic and Traumatology Department,*
[†]*Pathology Department,*
Selcuk University Medical Faculty, Konya, Turkey
[‡]*e-mail: myel@selcuk.edu.tr; musyel@hotmail.com*

Received July 13, 2000; Accepted August 5, 2000

ABSTRACT

A rare giant loose body in the knee joint and the treatment carried out were reported. Two loose bodies sized 5.5 and 1.5 cm were extracted from the knee of a patient who suffered from pain and knee motion restricted chronically. The histopathological evaluation revealed normal bone, hyaline cartilaginous tissue, and partly fibrocartilaginous tissue. These loose bodies suggested that they were separated in small pieces from the femoral condyles and were nourished by the synovial fluid. Over time, they adhered to each other in the knee joint.

Keywords: Loose body, Osteochondritis dissecans, Knee

INTRODUCTION

A loose body in a joint can be attributed to various factors, such as osteochondritis dissecans, osteochondral fracture, osteochondroma, synovial chondromatosis or fracture of osteophytes in osteoarthritis.[1, 2] Loose bodies are commonly involved in the knee joint and are well known in clinical practice.[2–4]

The case we report here is unusual as the loose body in the knee was quite large.

CASE REPORT

A 33-year-old amateur soccer player was seen by us in April 1994. He had pain, swelling, locking and palpable mass in the right knee. He had an injury in the knee after a fall 13 years ago. He mentioned a painful swelling and was advised to have an operation. However, he did not approve it.

Apart from an occasional pain, crepitus and swelling in the knee, he had no serious trouble

Correspondence to: Dr. Mustafa Yel, H Baybal cd., Tabipler sitesi No: 12, Nişantaş mah, Konya, Turkey.

until the last two months. Recently, he had felt a mobile mass in his right knee with his fingers.

On physical examination of the right knee, diffuse swelling (effusion), joint movement restriction especially flexion loss, mild instability, and quadriceps atrophy were found. Lateral roentgenogram showed a fragmented ossified mass situated between the patella, anterior femur and the tibia. On the antero-posterior roentgenogram, the bigger mass was superimposed between the intercondylar notch and over the lateral tibial condyle with partial overlap on the lateral femoral condyle; the small one was situated supero-lateral to the patella. Degenerative changes and crater-shape articular bone defects were seen on the medical femoral condyle (Fig. 1). Routine blood and urine examinations were within normal limits.

Diagnostic arthroscopy and removal of the loose body were recommended. During arthroscopic examination of the right knee, one osteochondral loose body about $1.5 \times 1.5 \times 1$ cm^3 was observed in the suprapatellar space. It was mobile and had the typical appearance of a loose body. Another giant osteochondral mass was situated between the anterior cruciate ligament, fat pad and lateral femoral condyle. Its size was $5.5 \times 5 \times 4$ cm^3 and was not fixed but too big to move in the knee. The weight-bearing area of the medial

(a) **(b)**

Fig. 1 **(a)** Lateral right knee roentgenogram showed a fragmented ossified bigger mass situated between the patella, anterior femur and tibia. **(b)** Antero-posterior roentgenogram showed medial femoral condyle defect and degenerative changes, the bigger mass partly superimposed between the femur and tibia, the smaller one was situated supero-lateral to the patella.

femoral condyle had crater lesions and degenerative changes. There were also degenerated medial meniscal tears. Other intra-articular structures were normal arthroscopically. Meniscal tears and irregular chondral flaps on the medial femoral condyle were debrided, and crater lesions were abraded. Lateral parapatellar incision was required to remove the loose bodies.

Gross examination of the loose bodies after removal revealed that the smaller one, which measured $1.5 \times 1.5 \times 1$ cm^3, was a typical ostechondral fragment. The bigger one which measured $5.5 \times 5 \times 4$ cm^3, was lobulated and covered with hyaline and partly with fibrocartilaginous tissue (Fig. 2). These fragments were not strongly adhered to each other and it was possible to separate them manually.

Histological examination revealed normal bone and hyaline cartilaginous tissue and fibrocartilaginous tissue between small particles. Cellular degenerative findings were found in some osseous area (Fig. 3).

At the sixth month of follow-up, the patient's knee range motion was 20° more than the preoperative level and his pain was less than the preoperative level. Although the range of motion was still good with less pain four years after the operation, degenerative changes increased considerably.

Fig. 2 The bigger mass which was measured $5.5 \times 5 \times 4$ cm^3 was lobulated and covered with hyaline and partly with fibrocartilaginous tissue.

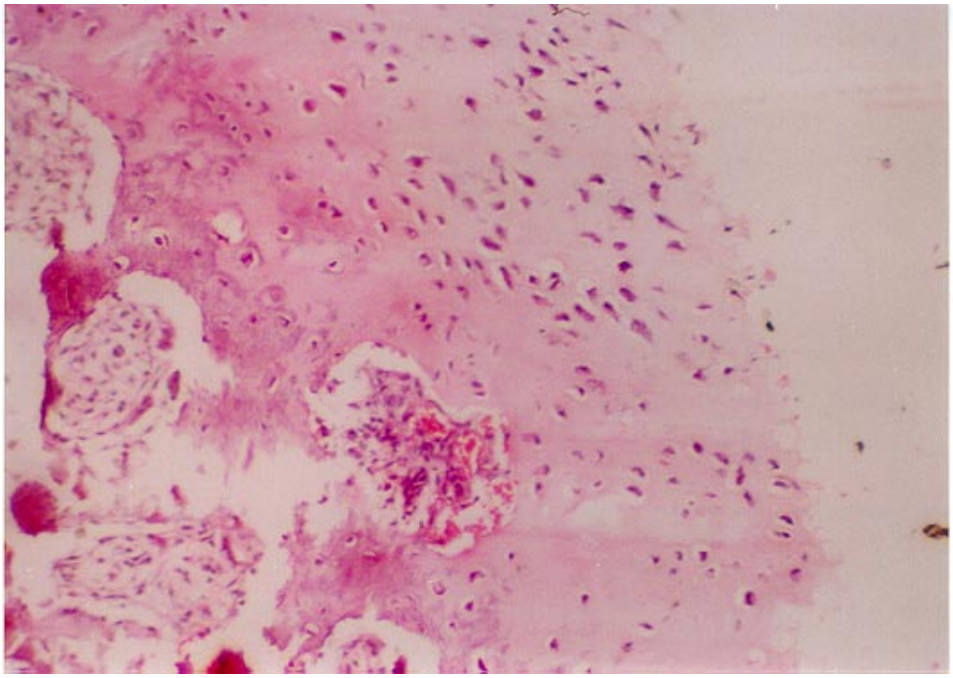

Fig. 3 Histological examination revealed normal bone, hyaline cartilaginous tissue and fibrocartilaginous tissue between small particles. Cellular degenerative findings were found in some osseous area.

DISCUSSION

Loose body in the knee joint resulting from various factors can be seen; most of them appear as osteochondritis dissecans which is a localized injury or condition affecting the articular surface that causes separation of segments from the cartilage and bone.[1–5] Weight-bearing surfaces of the medial and lateral femoral condyles are frequently involved.[1, 3, 4] Barrie[2] pointed out that osteocytes do not survive after detachment but chondrocytes do. The mesenchymal cells of the marrow may do as well. Fibrocartilaginous metaplasia of the chondrocytes and growth of the loose body nourished by the synovial fluid have been well described for over 100 years.[2, 6, 8]

Sarmiento and Elkins[7] reported a similar case in the knee joint with a history of an injury followed by swelling 13 years later and surgical removal after another seven years. Das and Mukherjee[3] reported another case similar to a history of an injury 15 years ago. Histologically, it is difficult to determine the origin of an osteochondral loose body. Sarmiento and Elkins[7] were not sure whether the osteochondromatous mass was a chondroma or the result of an osteochondral fracture but they pointed out that the mass fitted well into tibial fracture site. In the report by Das and Mukherjee,[3] the mass seemed to originate from the site of a previous tibial ostechondral fracture.

The patient had many different sized osteochondral craters and serious degeneration on the weight-bearing surface of the medial femoral condyle. This giant loose body suggested that it originated from the osteochondral fragments separated from the medial femoral condyle, and these fragments were nourished by the synovial fluid and adhered each other with peripheral fibrocartilaginous tissue. The fact that the surface

of the mass was lobulated and easily breakable into harder and smaller fragments supported the way the loose body formed.

References

1. Aichroth P. Osteochondritis dissecans of the knee. A clinical survey. *J Bone Joint Surg* **53B**:440–447, 1971.
2. Barrie HJ. Intra-articular loose bodies regarded as organ cultures *in vivo*. *J Path* **125**:163–168, 1978.
3. Das AK, Mukherjee DR. Giant osteochondral loose body of the knee joint. *J Bone Joint Surg* **60A**:559–560, 1978.
4. Ewing JW, Voto SJ. Arthroscopic surgical management of osteochondritis dissecans of the knee. *Arthroscopy* **4**: 37–40, 1988.
5. Letson GD, D'Ambrosia RD. Osteochondritis dissecans. *Orthopedics* **10**:1187–1189, 1987.
6. McGinty JB. Arthroscopic removal of loose bodies. *Orthop Clin North Am* **13**:313–328, 1982.
7. Sarmiento A, Elkins RW. Giant intra-articular ostechondroma of the knee. *J Bone Joint Surg* **57A**: 560–561, 1975.
8. Schenck RC, Goodnight JM. Current concept review. Osteochondritis dissecans. *J Bone Joint Surg* **78A**: 439–456, 1996.