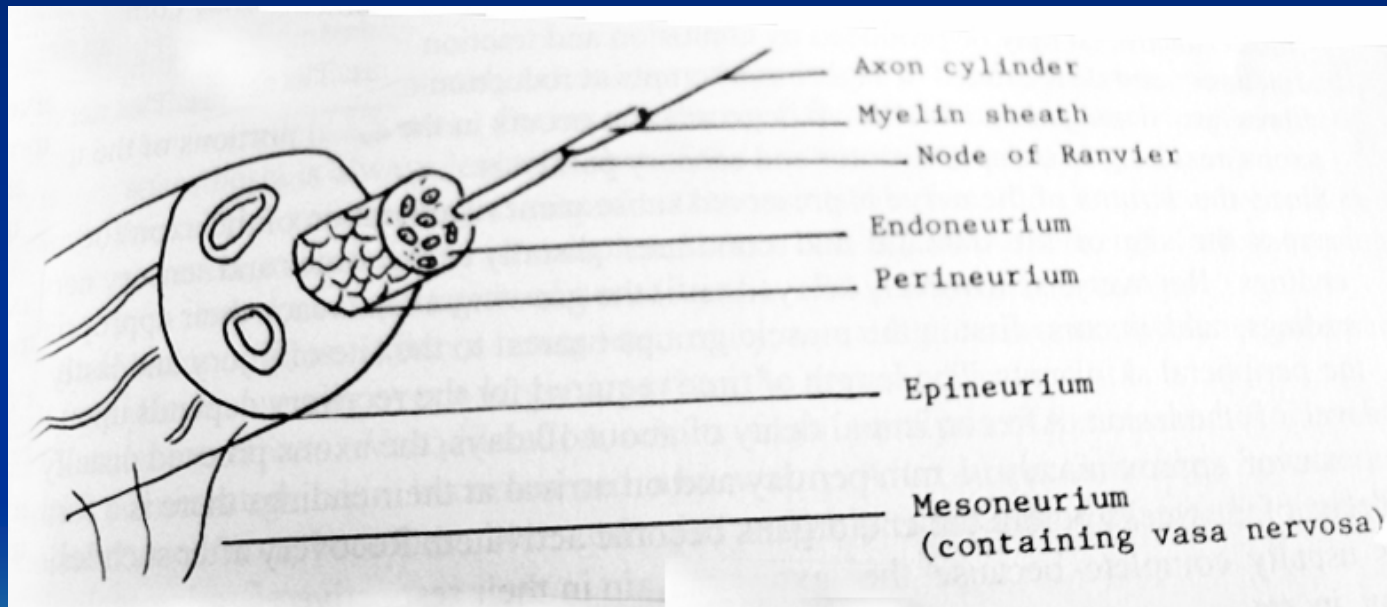


Nerve Types

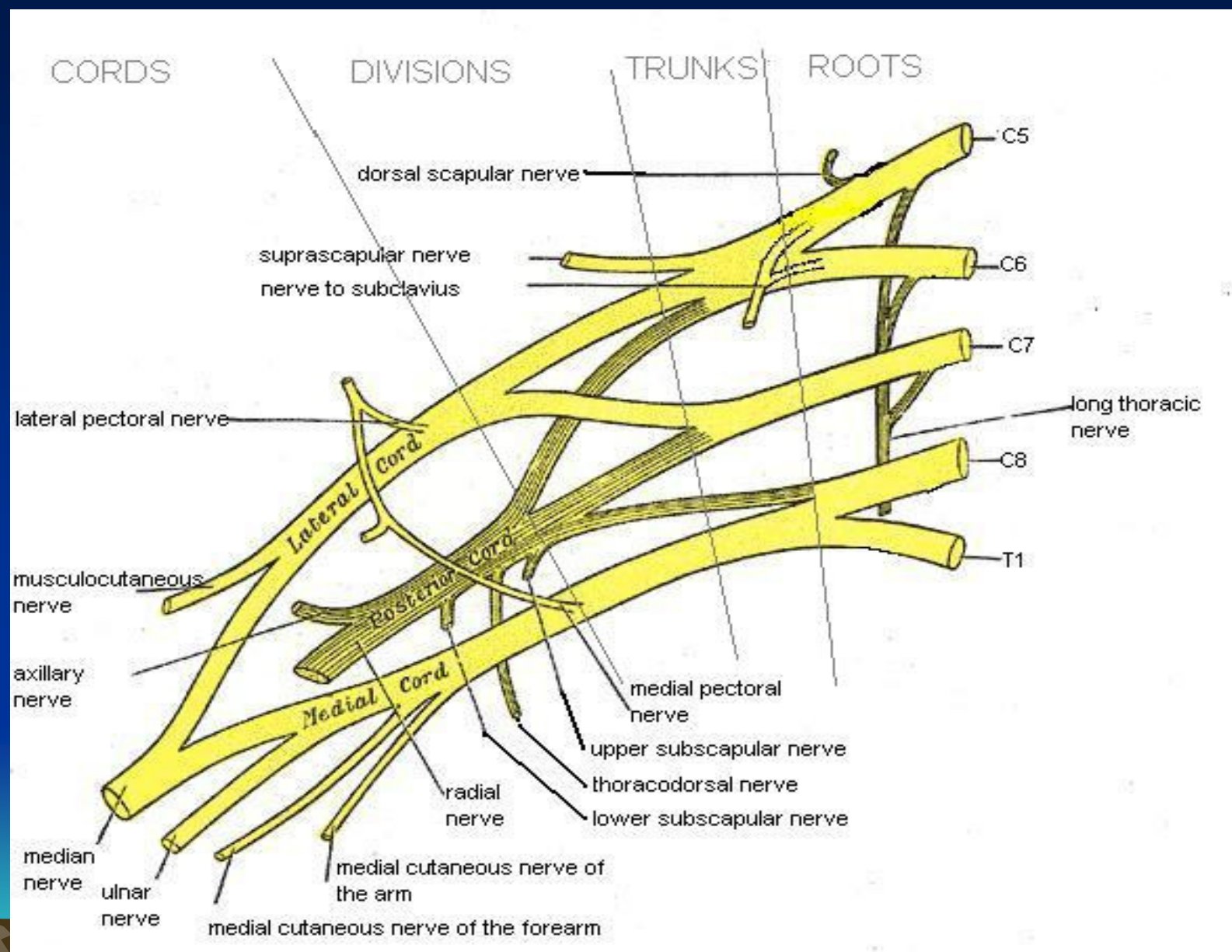
NON-Medullated
Medullated



Nerve Injuries

- Injuries (Open / Closed)
- Local causes (Pressure, Infiltration)
- Systemic disease (Syphilis / Leprosy)





CORDS

DIVISIONS

TRUNKS

ROOTS

dorsal scapular nerve

suprascapular nerve
nerve to subclavius

lateral pectoral nerve

Lateral Cord

musculocutaneous nerve

axillary nerve

Posterior Cord

medial pectoral nerve

upper subscapular nerve

thoracodorsal nerve

lower subscapular nerve

median nerve

ulnar nerve

medial cutaneous nerve of the arm

medial cutaneous nerve of the forearm

long thoracic nerve

C5

C6

C7

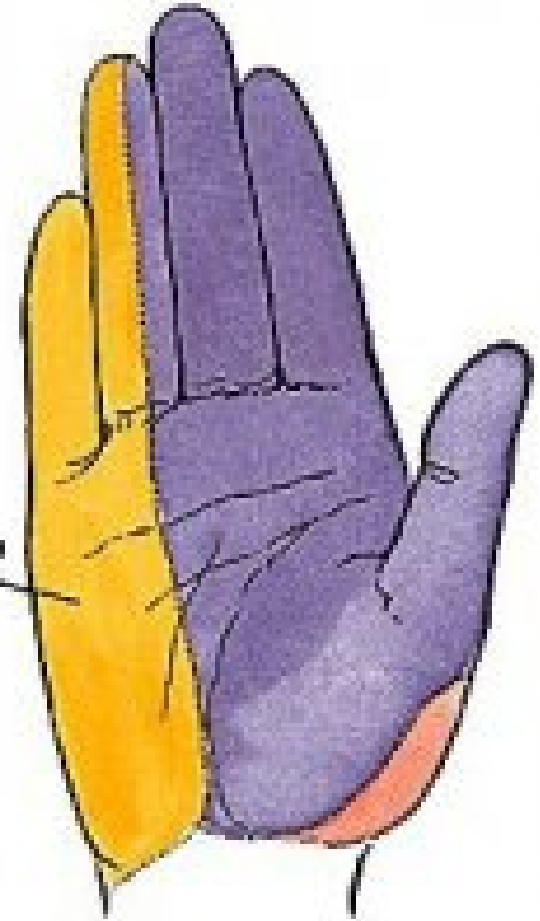
C8

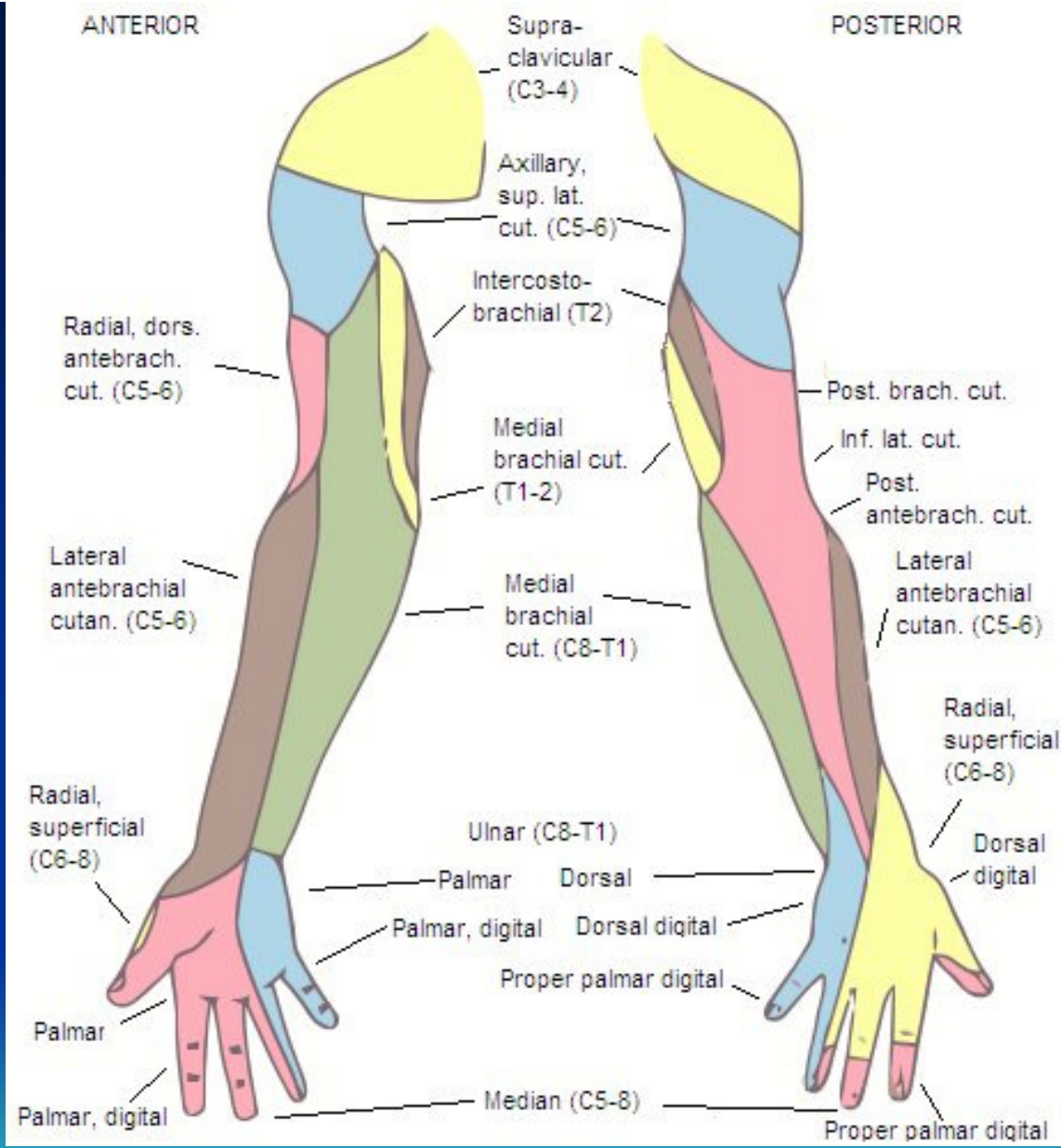
T1

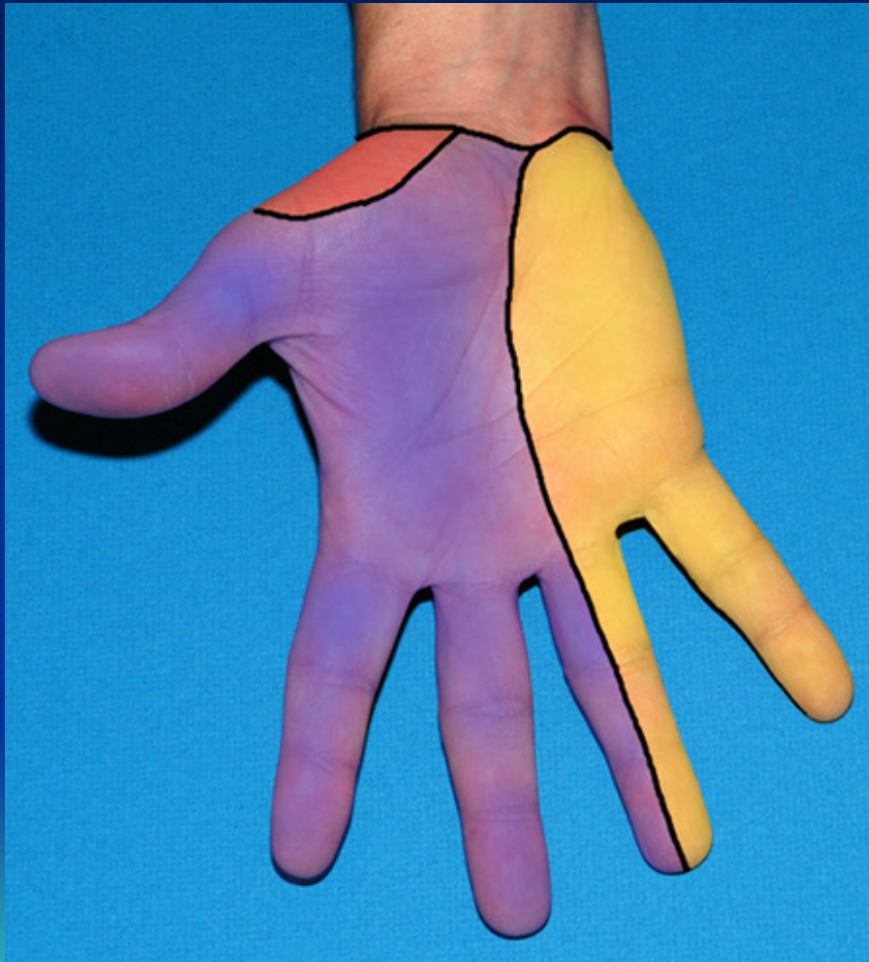

Figure 2

Cutaneous innervation
of the ulnar nerve





**Pronator
teres**

**Flexor
carpi
radialis**

Radius

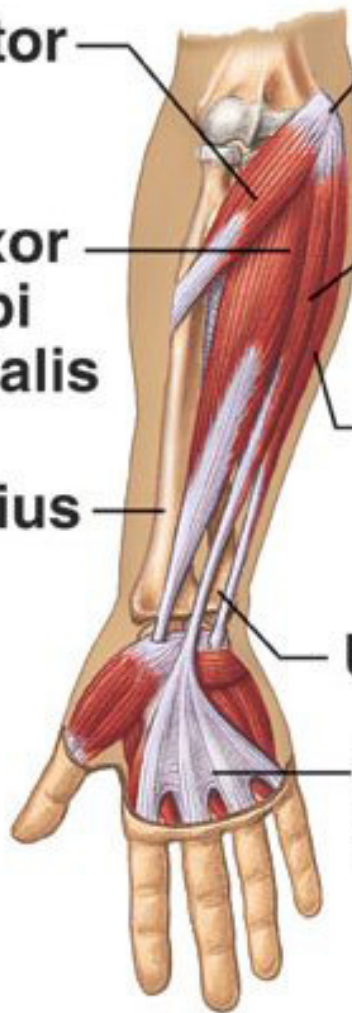**Medial
epicondyle
of humerus**

**Palmaris
longus**

**Flexor carpi
ulnaris**

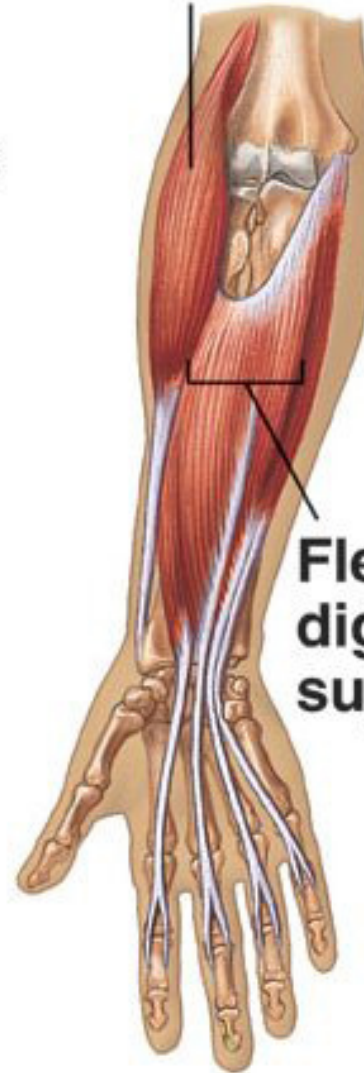Ulna

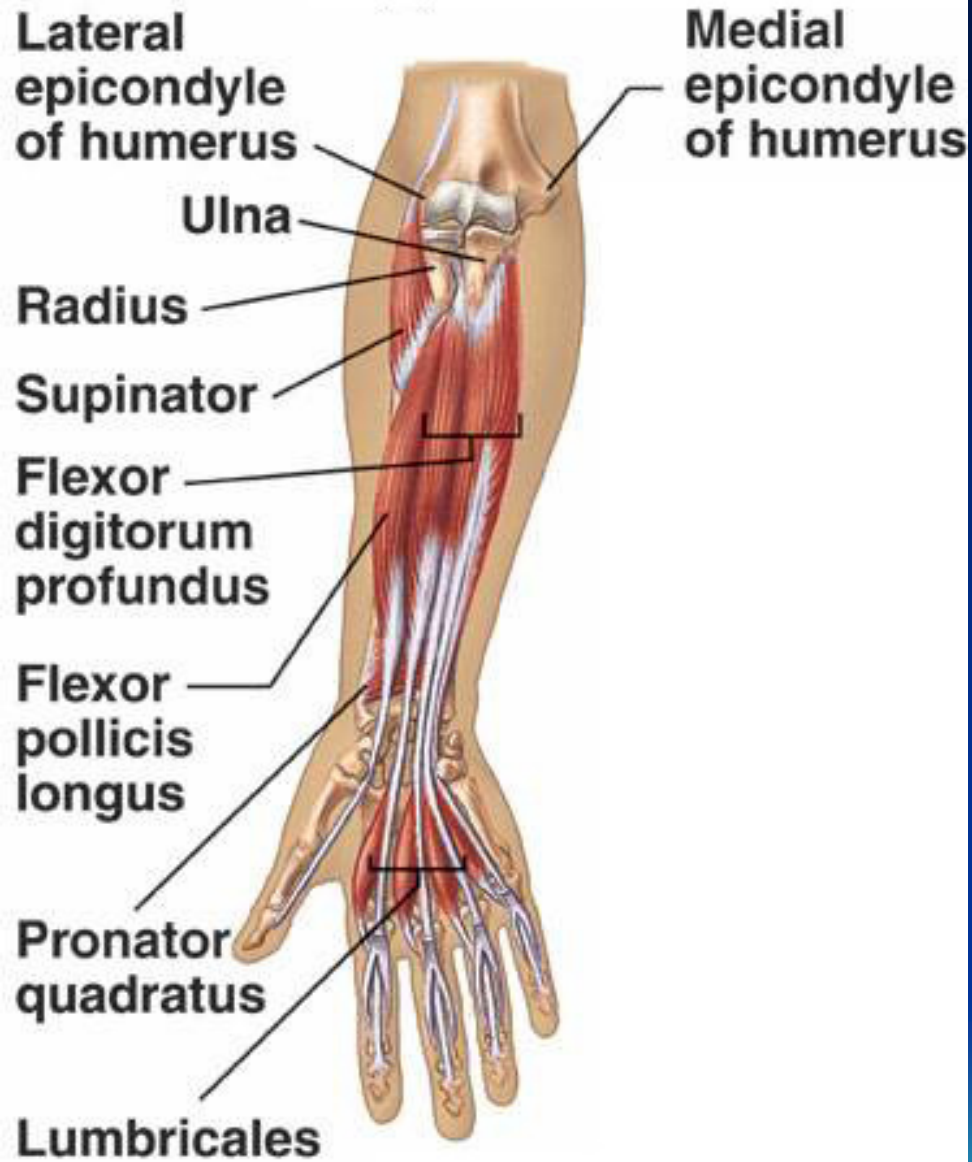
**Palmar
aponeurosis**



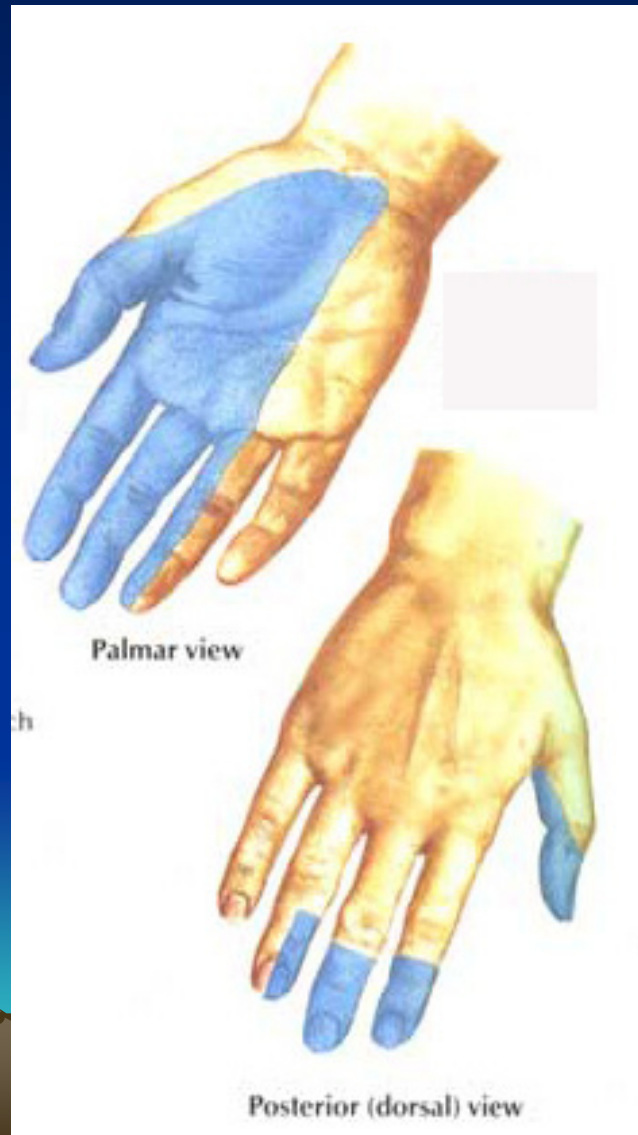
Brachioradialis

**Flexor
digitorum
superficialis**

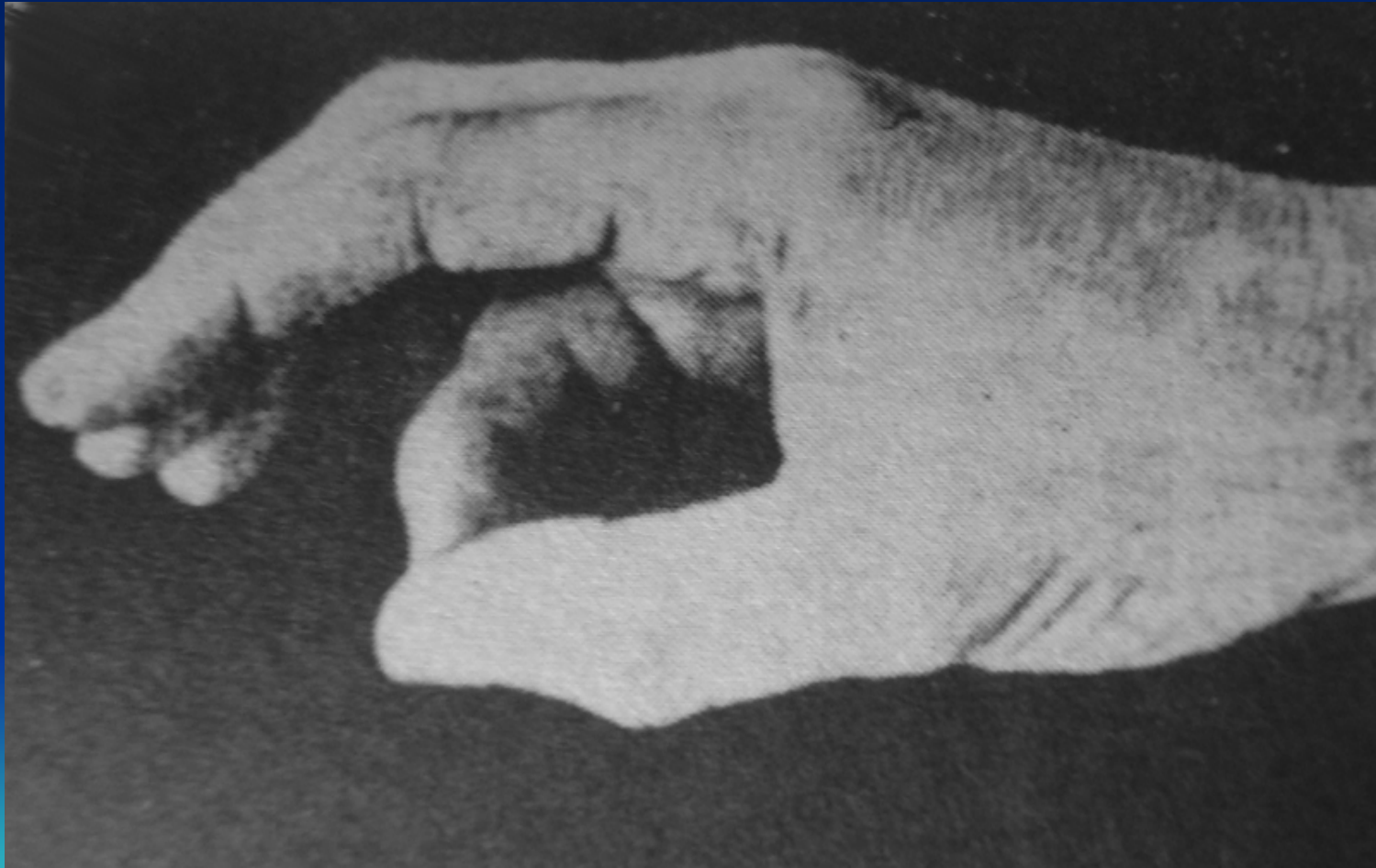



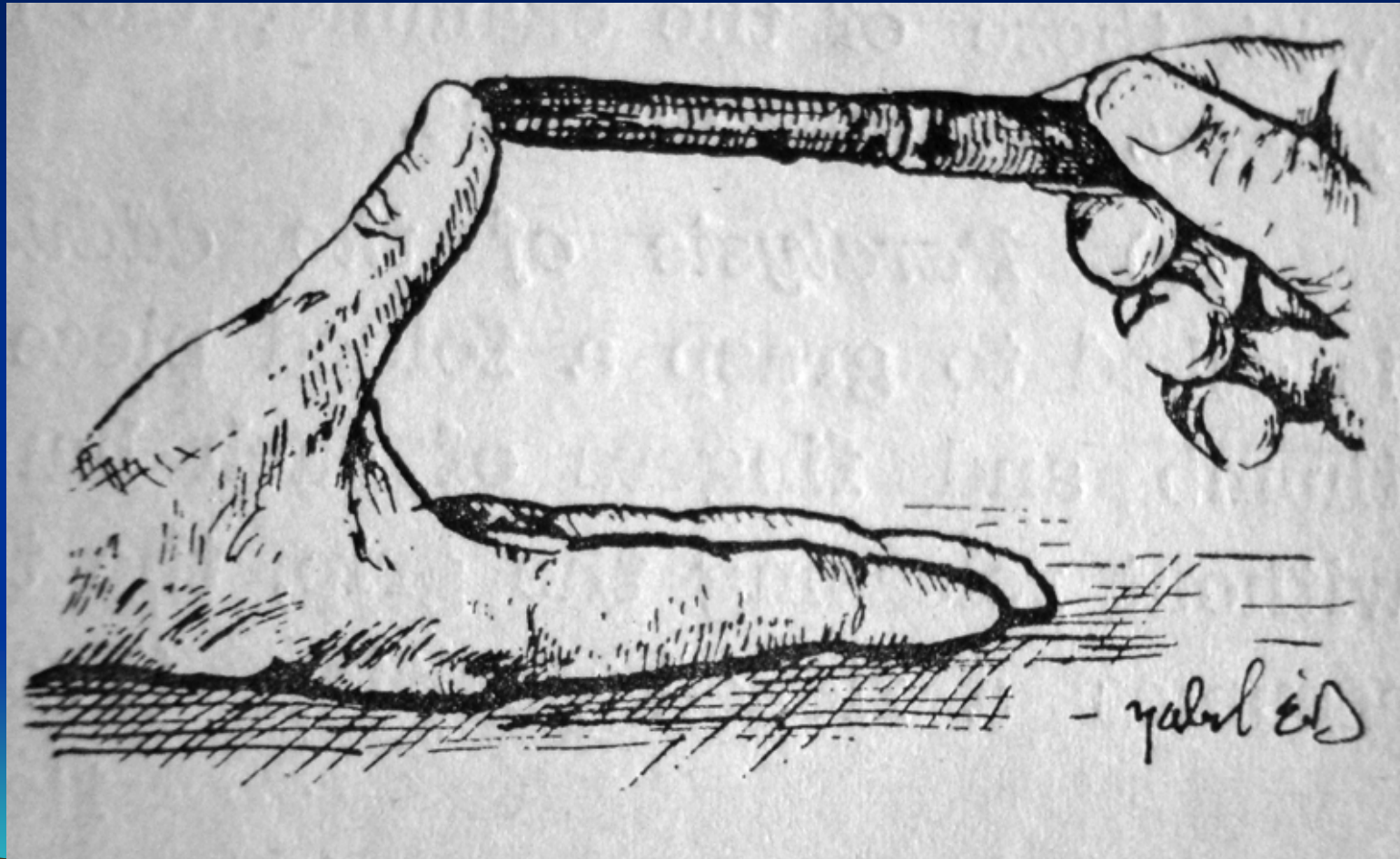
Median Nerve Injury



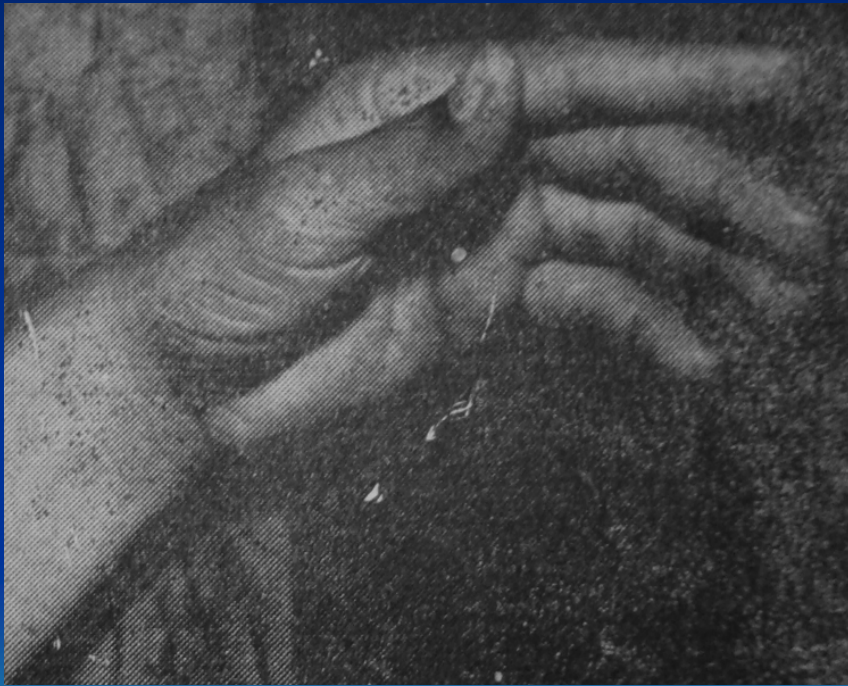Median Nerve Injury



Median Nerve Injury

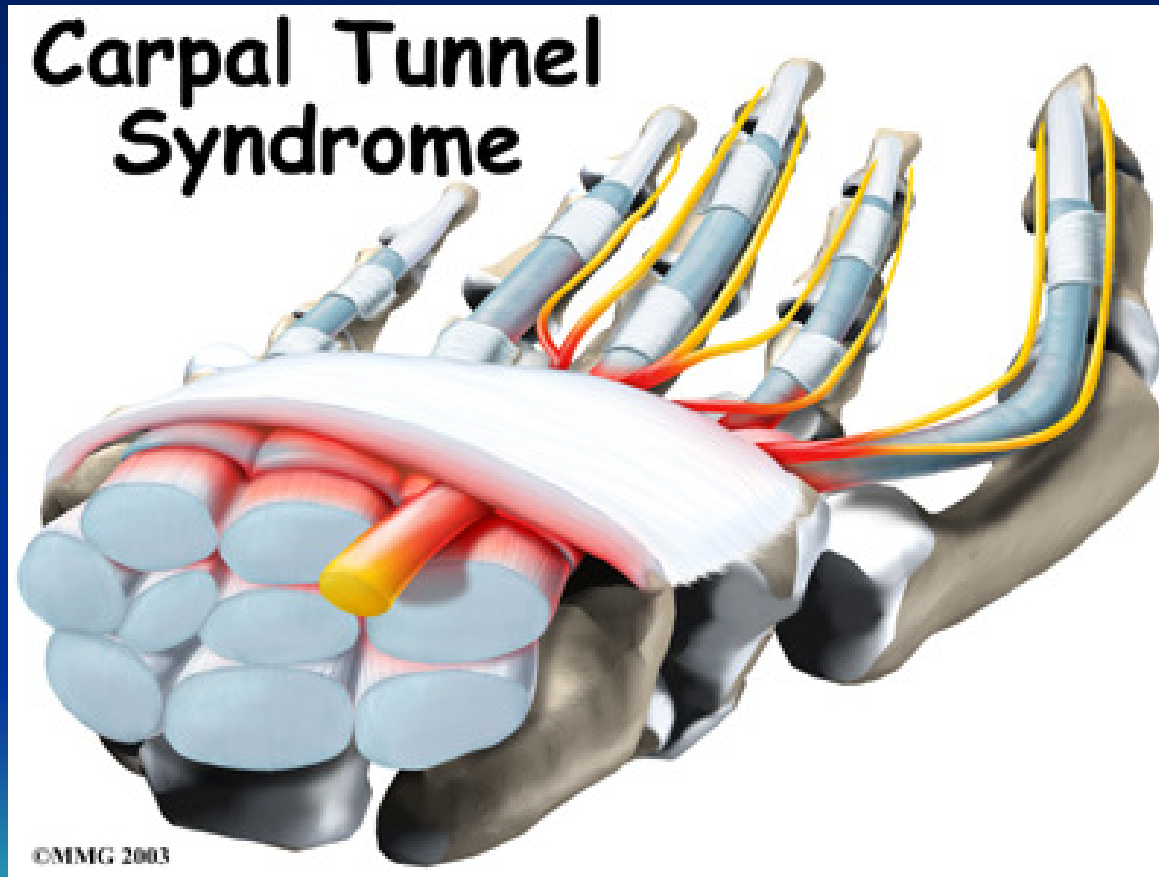


Median Nerve Injury



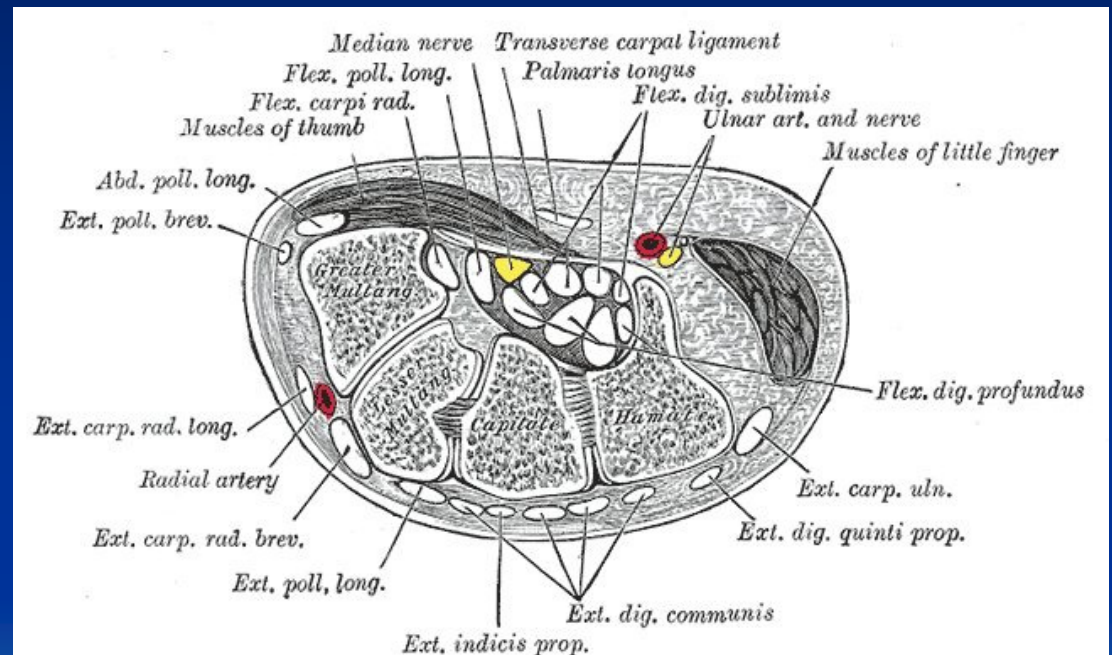
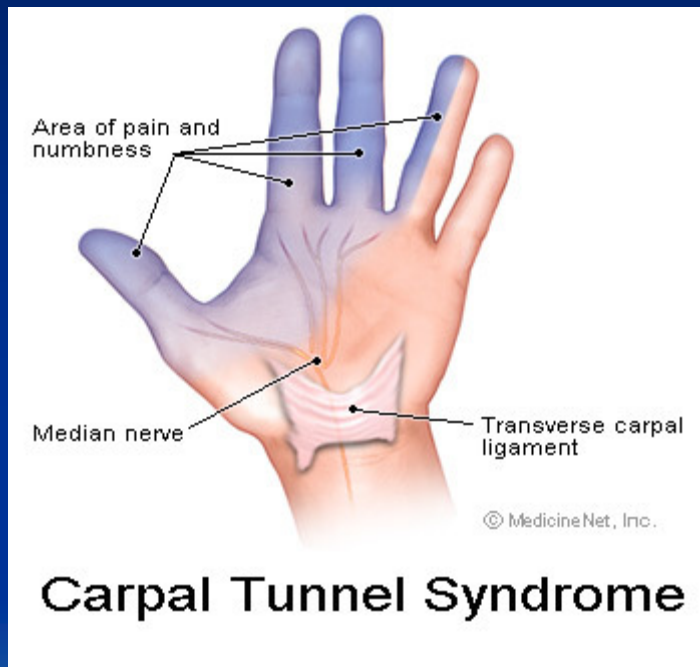
Median Nerve Injury

Carpal Tunnel Syndrome

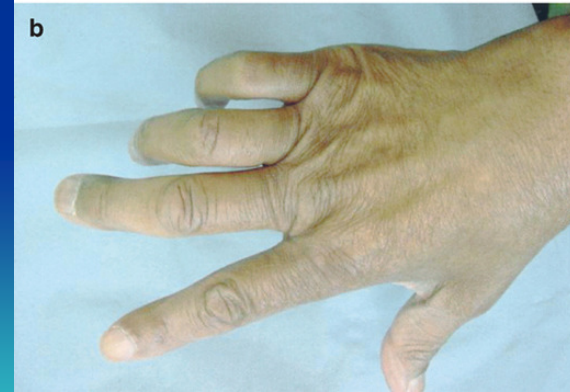
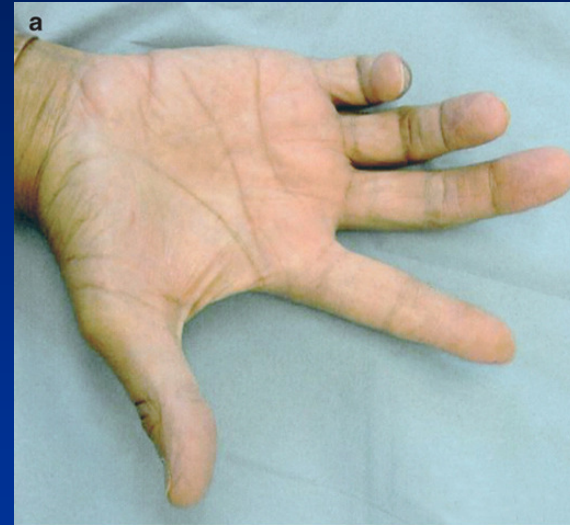
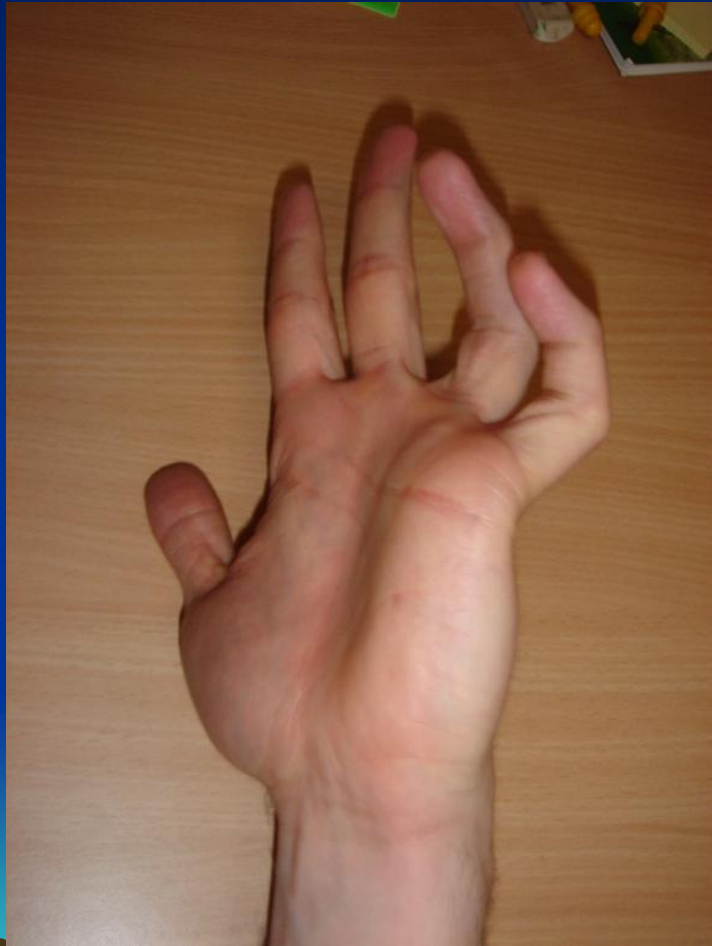Median Nerve Injury

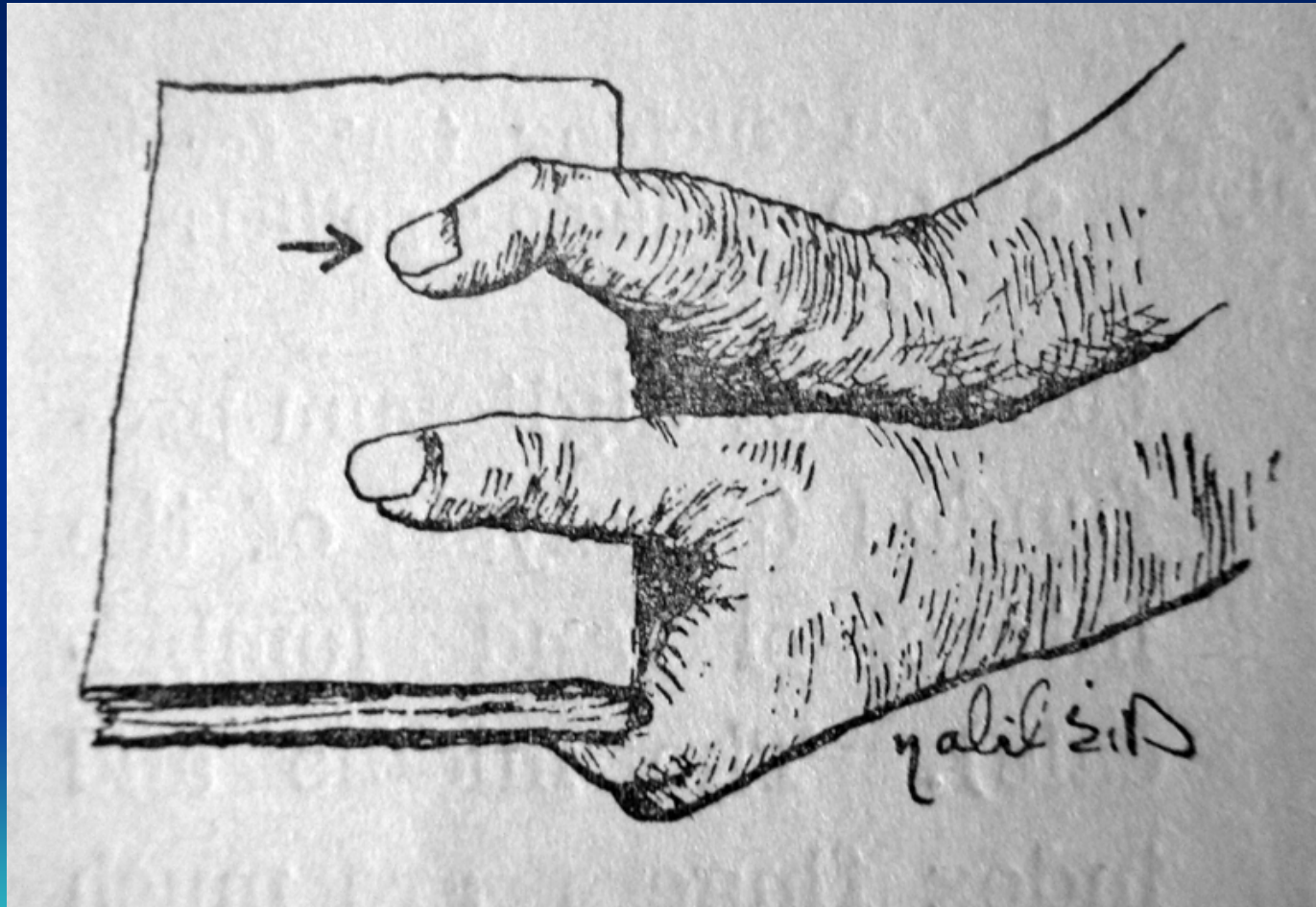
Carpal Tunnel Syndrome



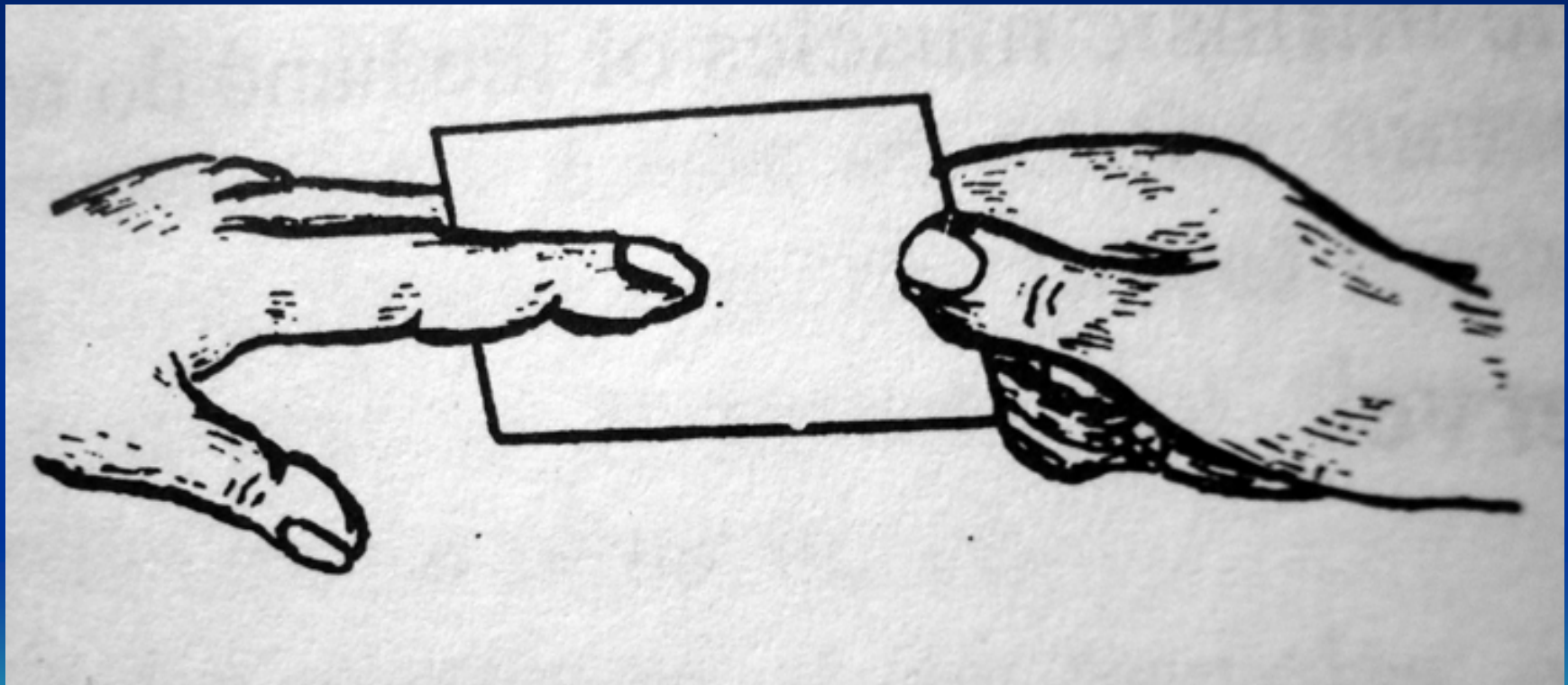
Ulnar Nerve Injury



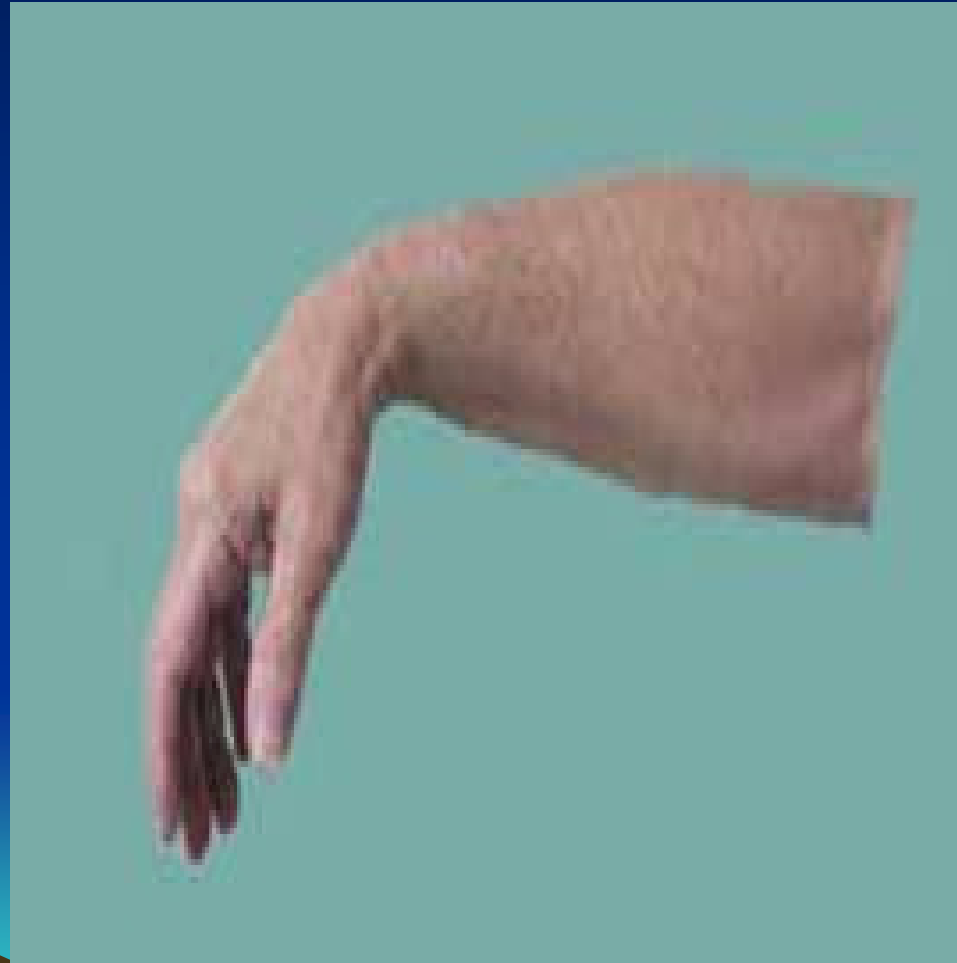Ulnar Nerve Injury



Ulnar Nerve Injury



Radial Nerve Injury



Nerve Tumors

1- Neurofibroma

Origin Schwann Cells / Nerve passes through tumour

1- Generalized Neurofibromatosis

Autosomal dominant

Along nerves (Mobile across but not along)

Multiple / fusiform / firm or soft / Café Au lait

Sacromatous change (trauma / incomplete excision)

Can be associated with Meningioma, glioma

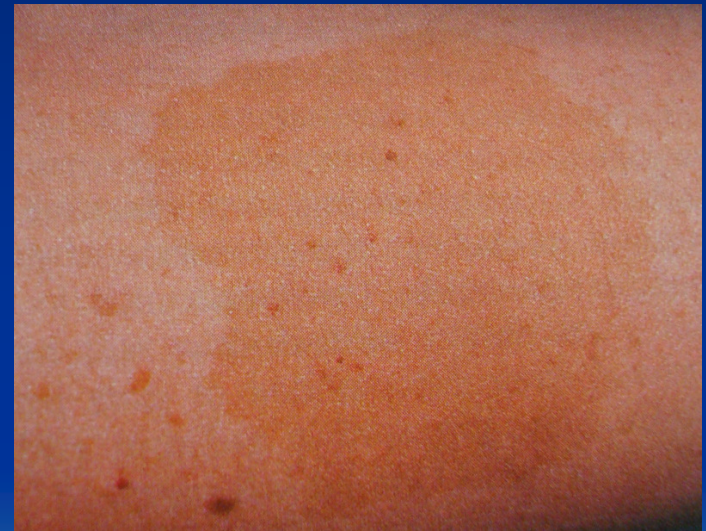2- Localized Neurofibromatosis

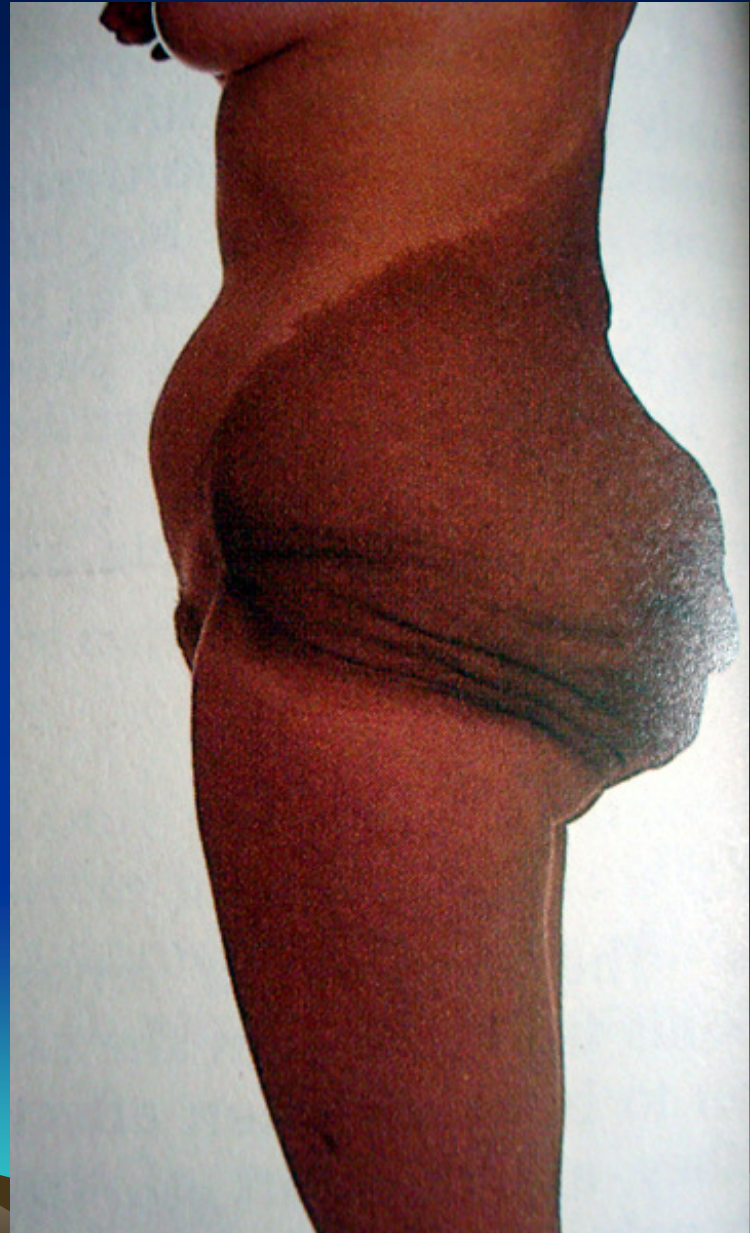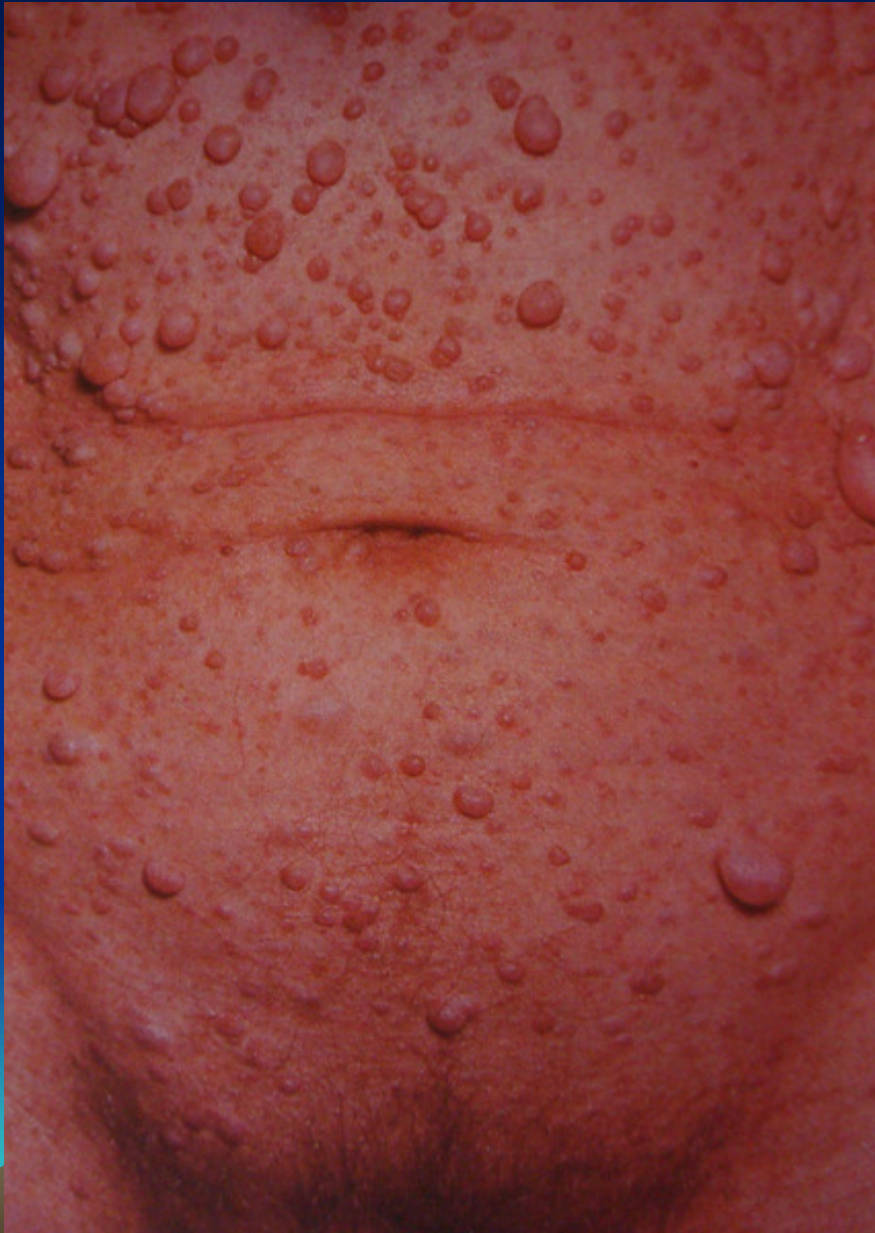3- Moluscum Fibrosum

Cutaneous nerves / soft / any where but palm and sole

4- Plexiform neuroma (Pachydermatocele)

5th nerve branches (markedly thickened nerve & skin)





Nerve Tumors

2- Schwannoma (Neurolemmoma)

Origin Schwann Cells

Nerve stretched over not passing through tumour

Solitary / Benign with **no malignant transformation**

Auditory nerve

Acoustic neuroma (projects into CP angle compressing 5th, 6th & 7th nerve)



Nerve Tumors

3- Neurofibrosarcoma

De Novo or on top of neurofibroma

Rapid growth, pain

Infiltrates surroundings

Wide excision with safety margin



Nerve Tumors

4- Meningioma

- From arachnoid fibroblasts
- On deep surface of dura and arachnoid in relation to base of skull, superior sagittal sinus, transverse sinus or falx cerebri
- Psammoma bodies under ME :arachnoid cells arranged in whorly appearance with central calcification
- Infiltrates surroundings
- Wide excision with safety margin

